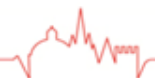



# Imaging of the left atrial appendage and device placement

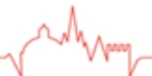Jim Newton  
Consultant Cardiologist  
Oxford Heart Centre  
[Jim.Newton@orh.nhs.uk](mailto:Jim.Newton@orh.nhs.uk)

No conflict of interest to declare

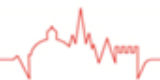

# Imaging the left atrial appendage

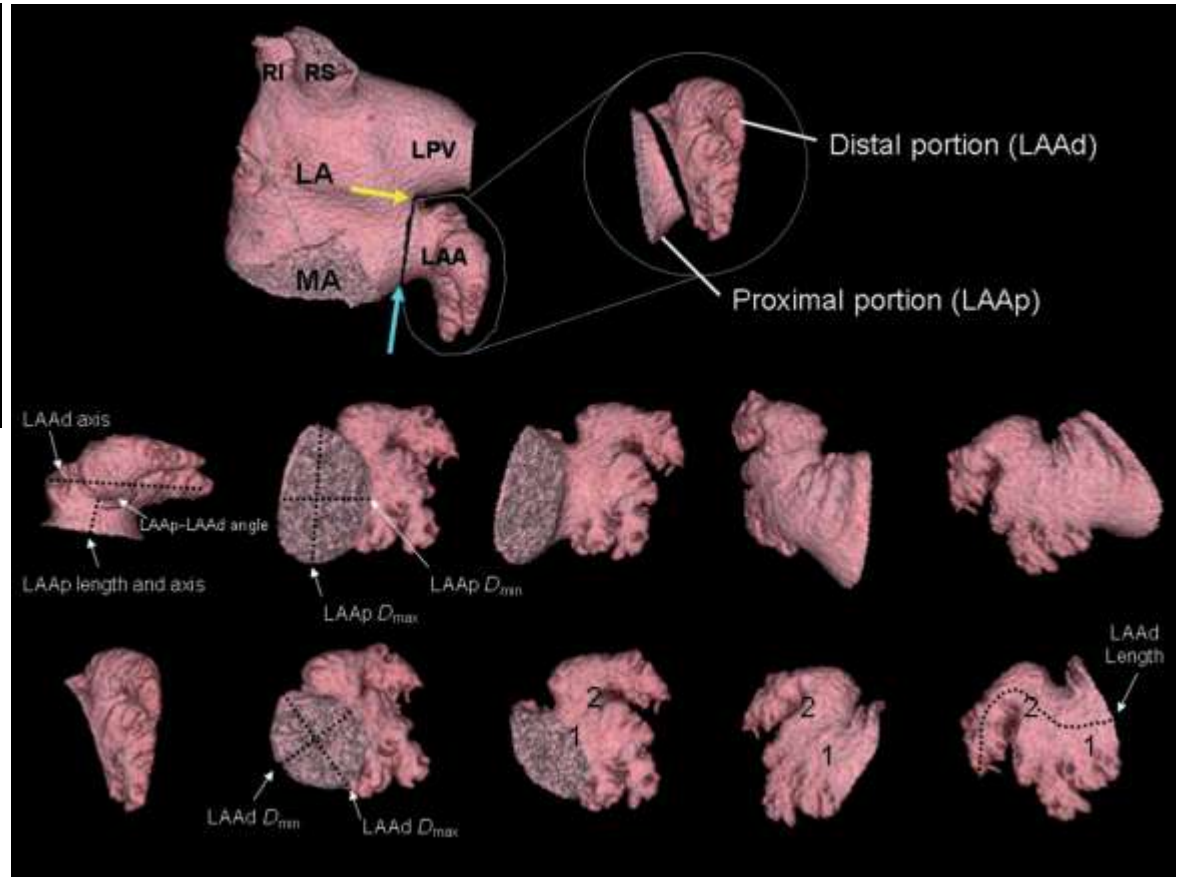
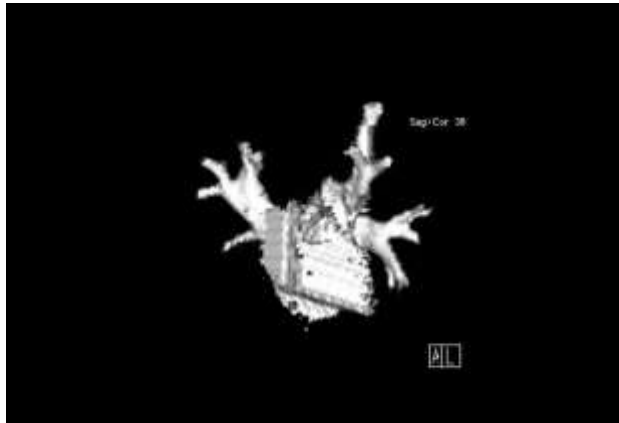
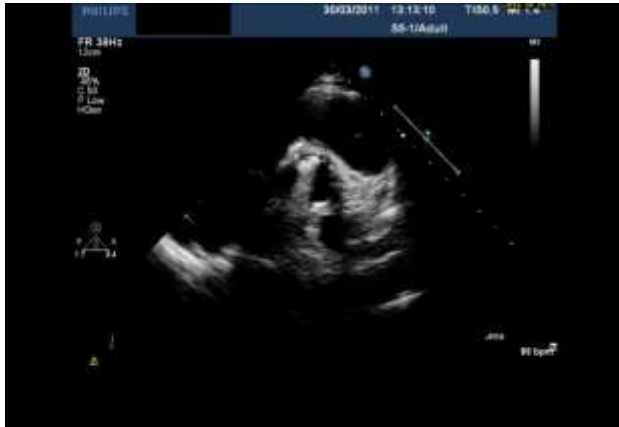- Understand the appendage anatomy
- Exclude appendage thrombus
- Guide device selection and sizing
- Guide deployment and identify complications
- Assess result of deployment and follow up



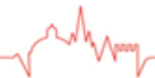# Challenge for imaging



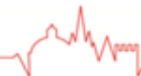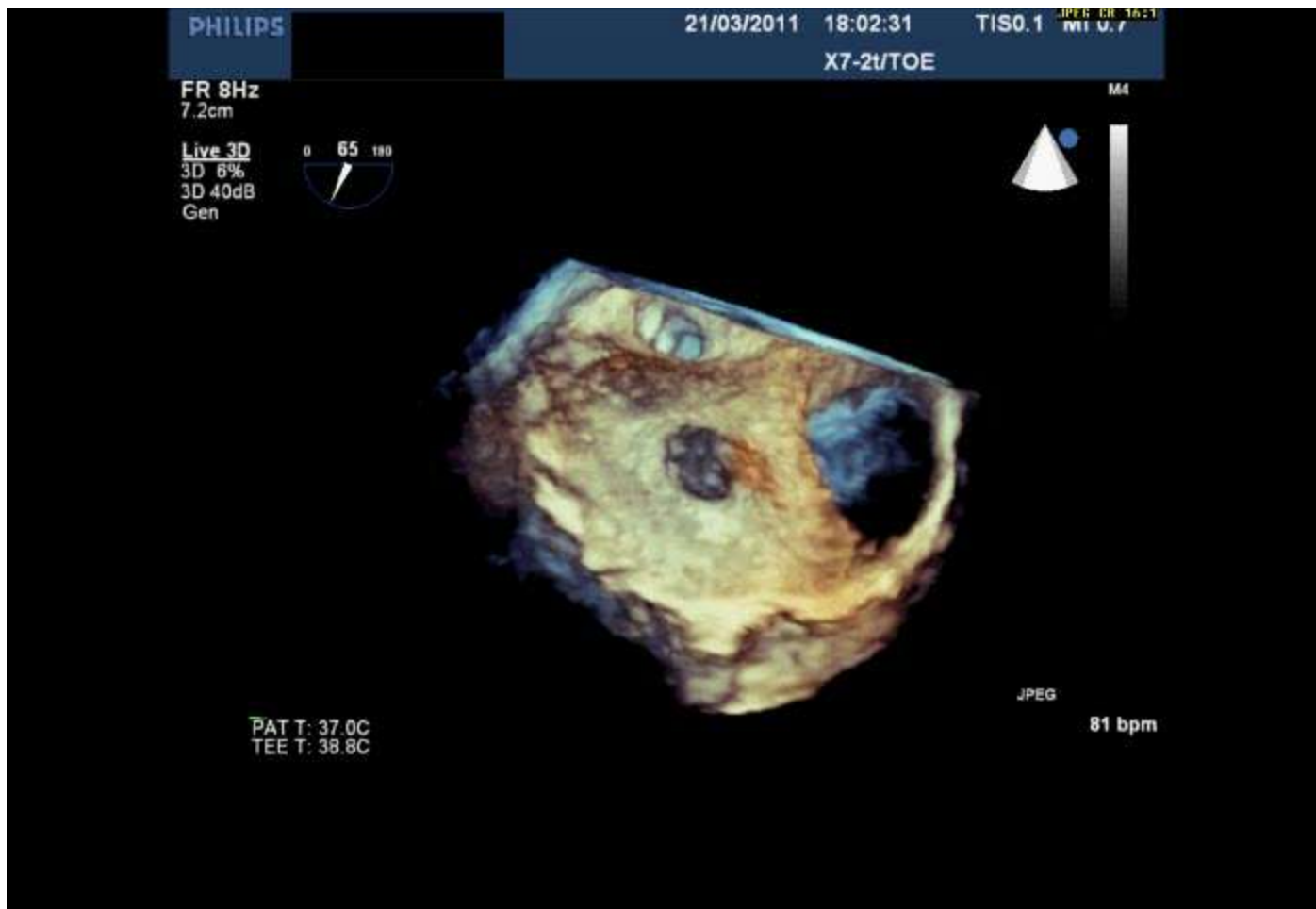# Other modalities



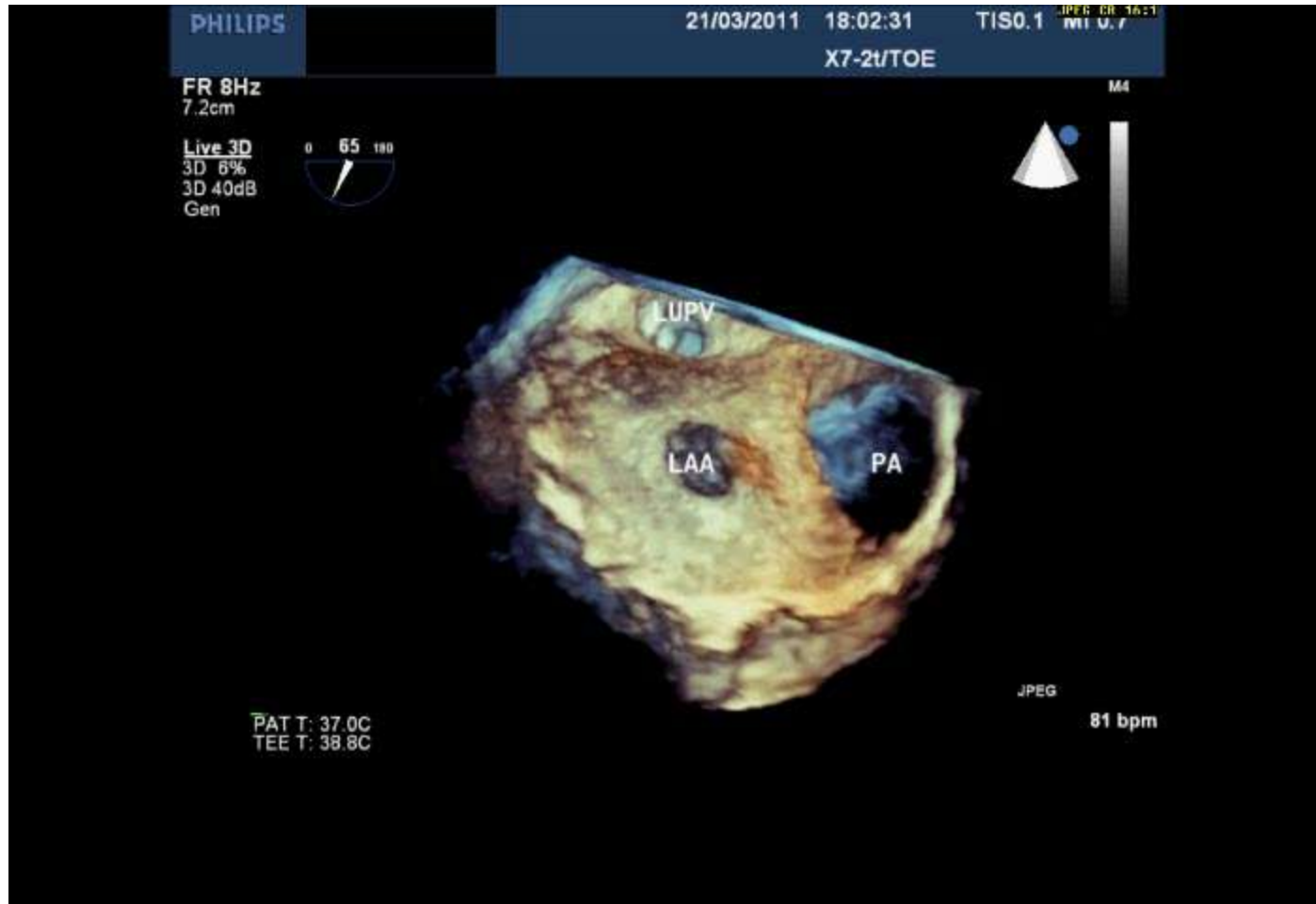
Lacomis JM, *Europace* 2007;9:1134-1140



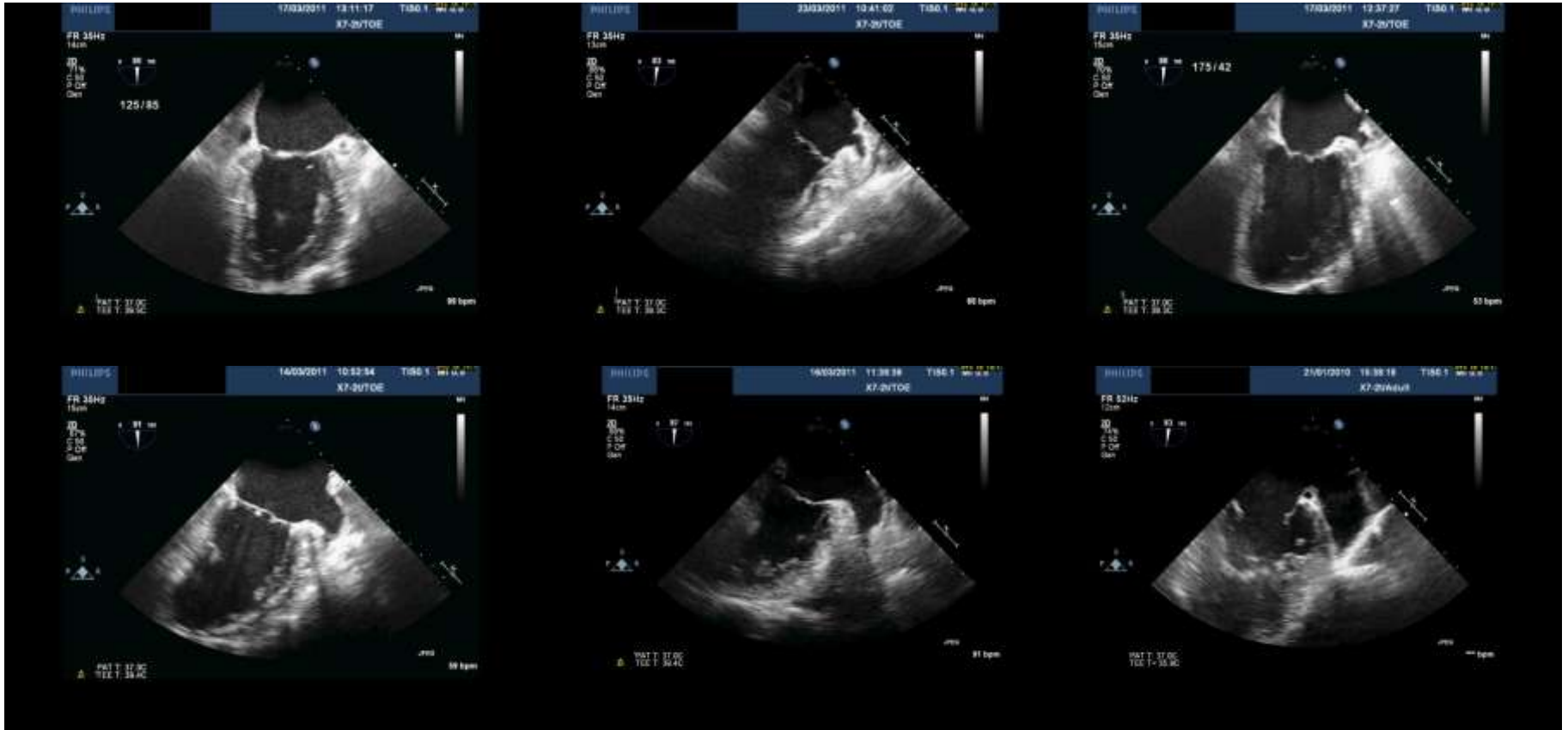# Understand the anatomy



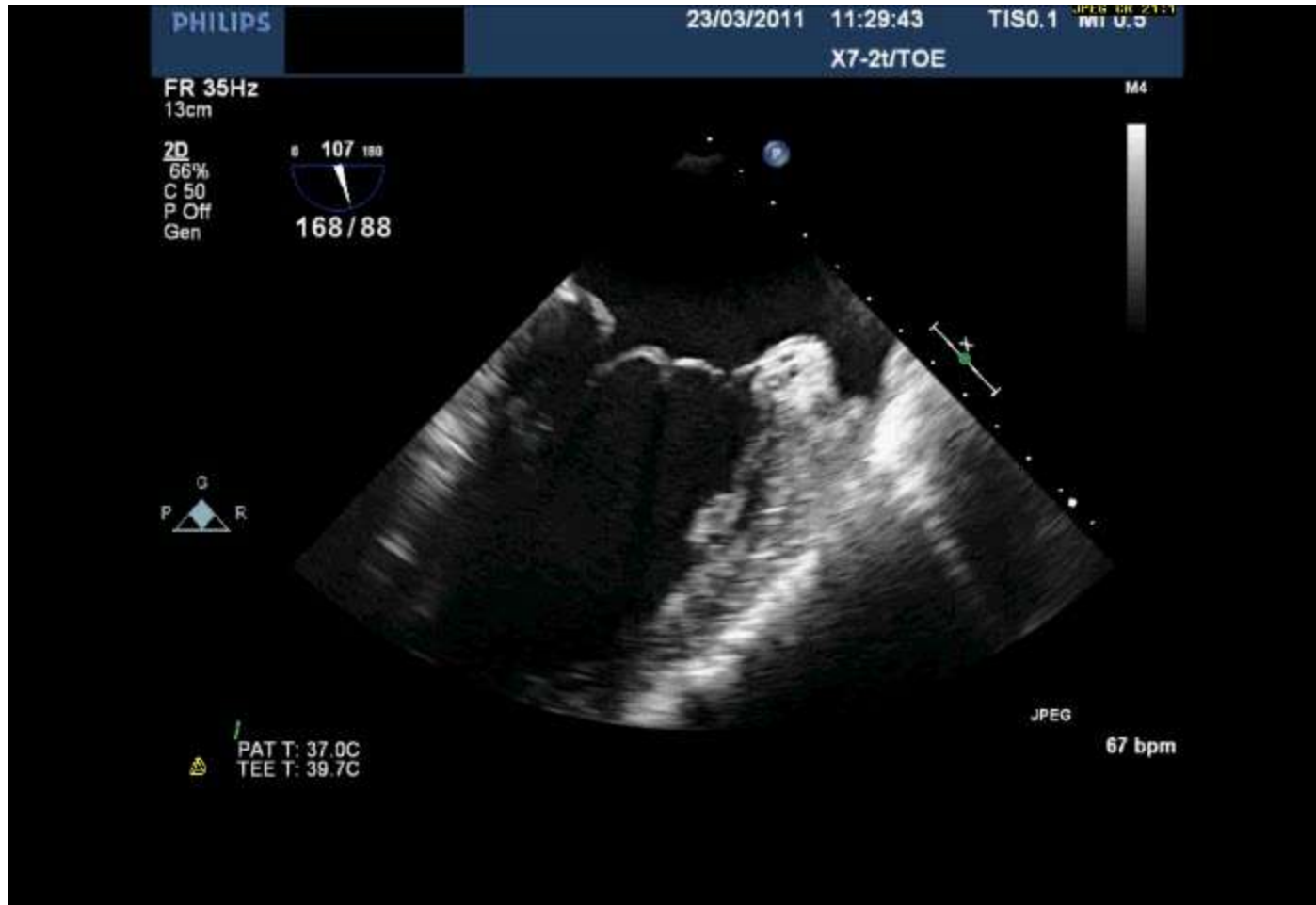# Understand the anatomy



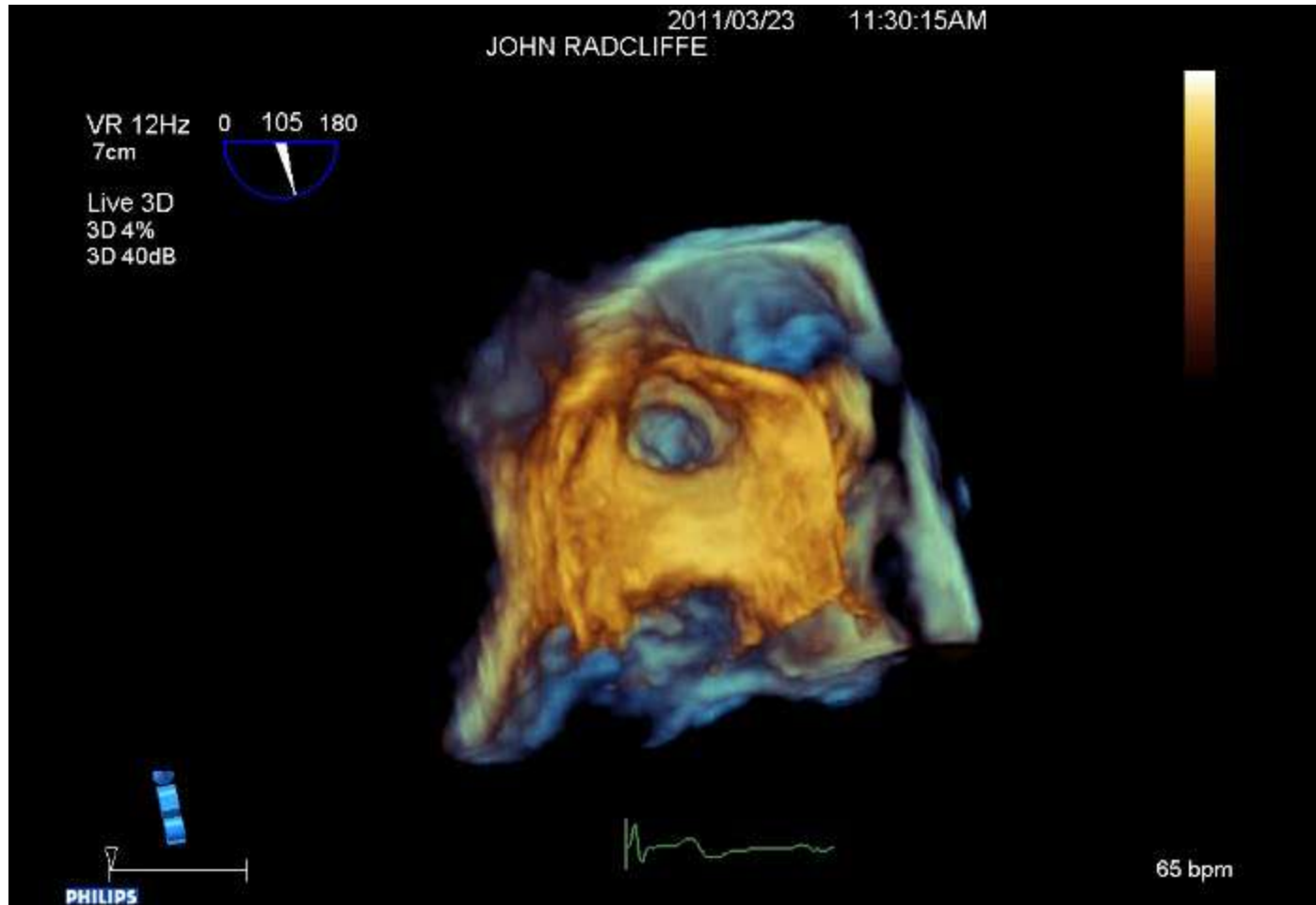
# All different shapes and sizes



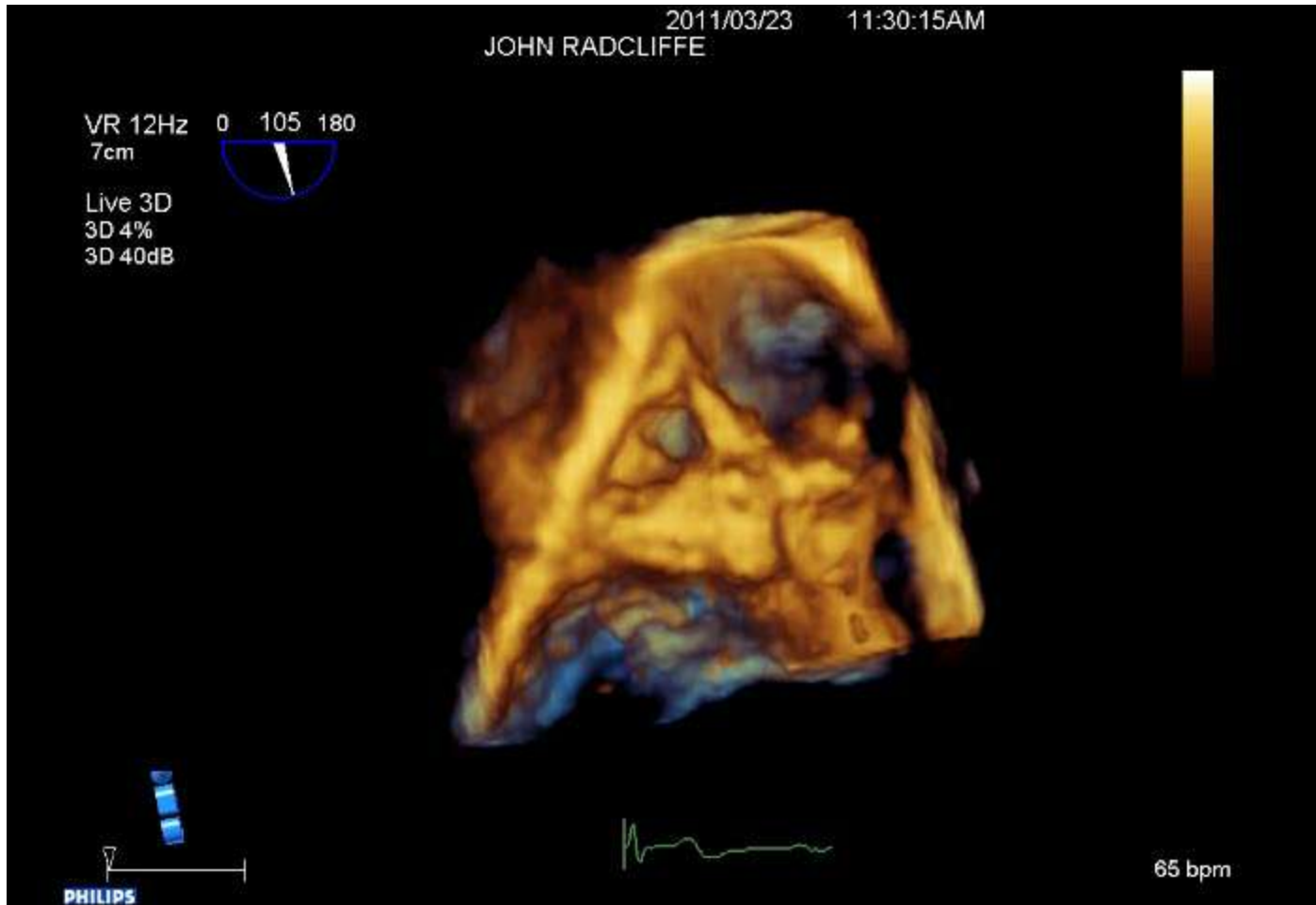
# Expect more than one lobe



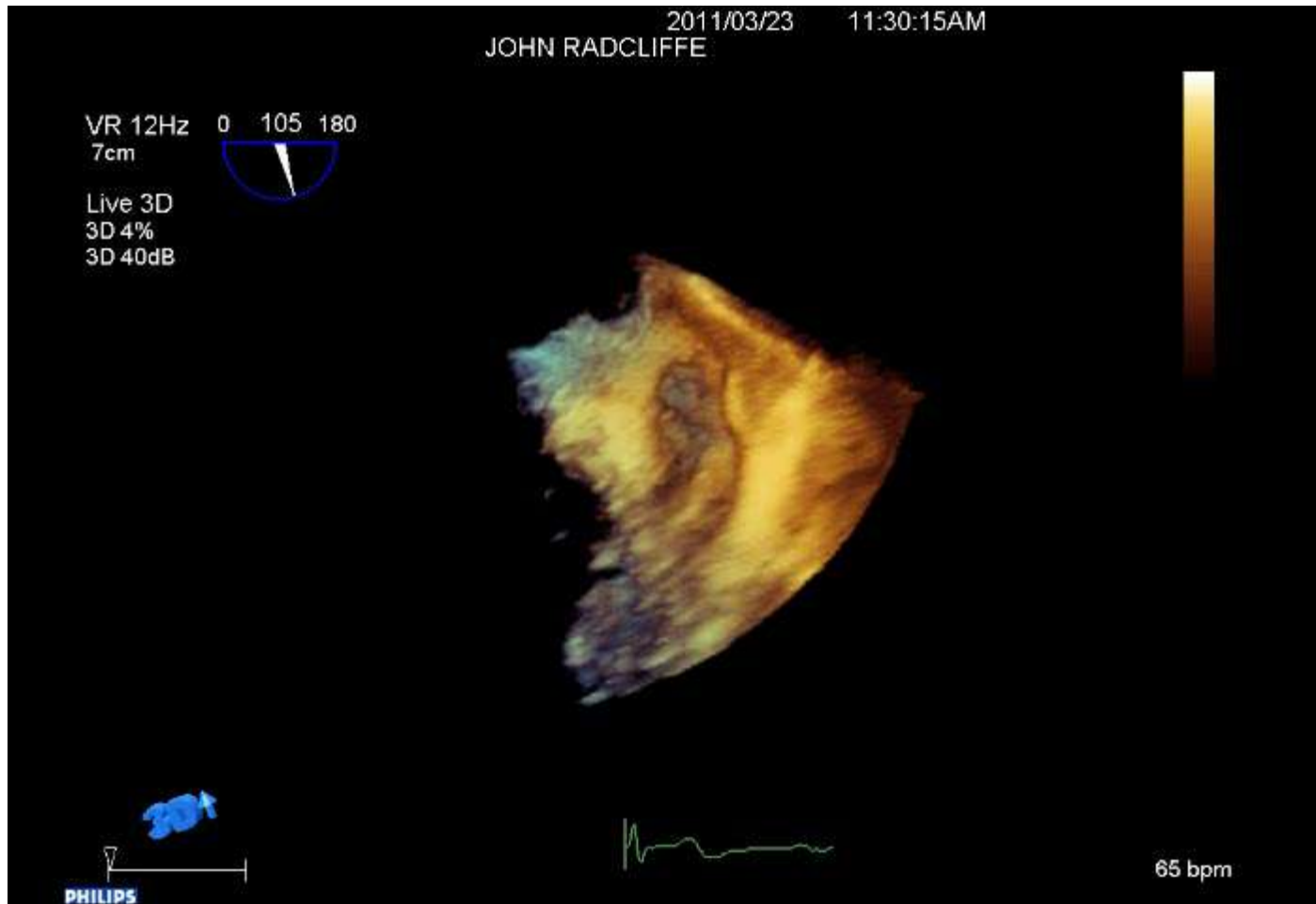
# Expect more than one lobe



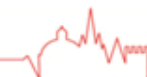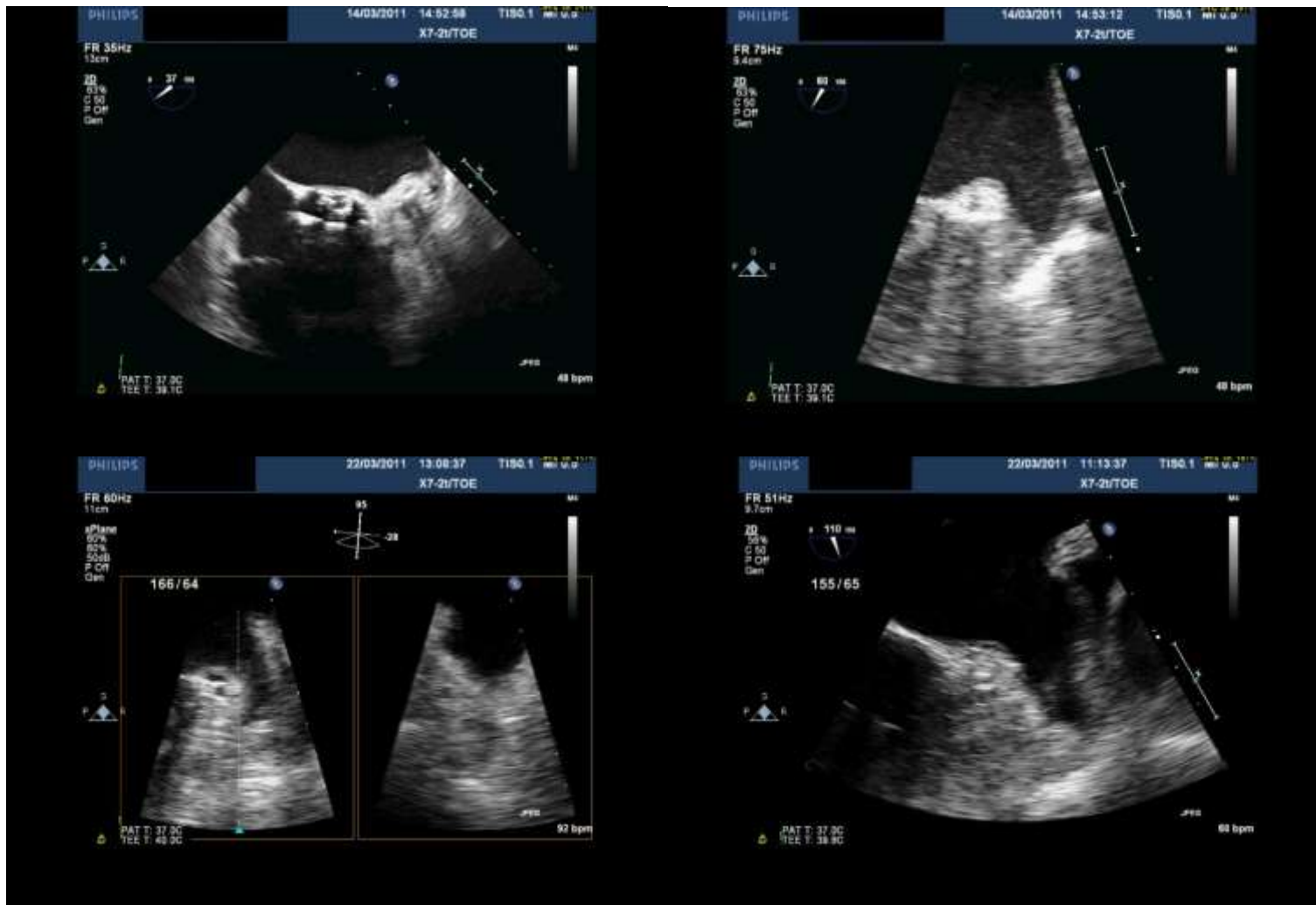
# Understand the anatomy



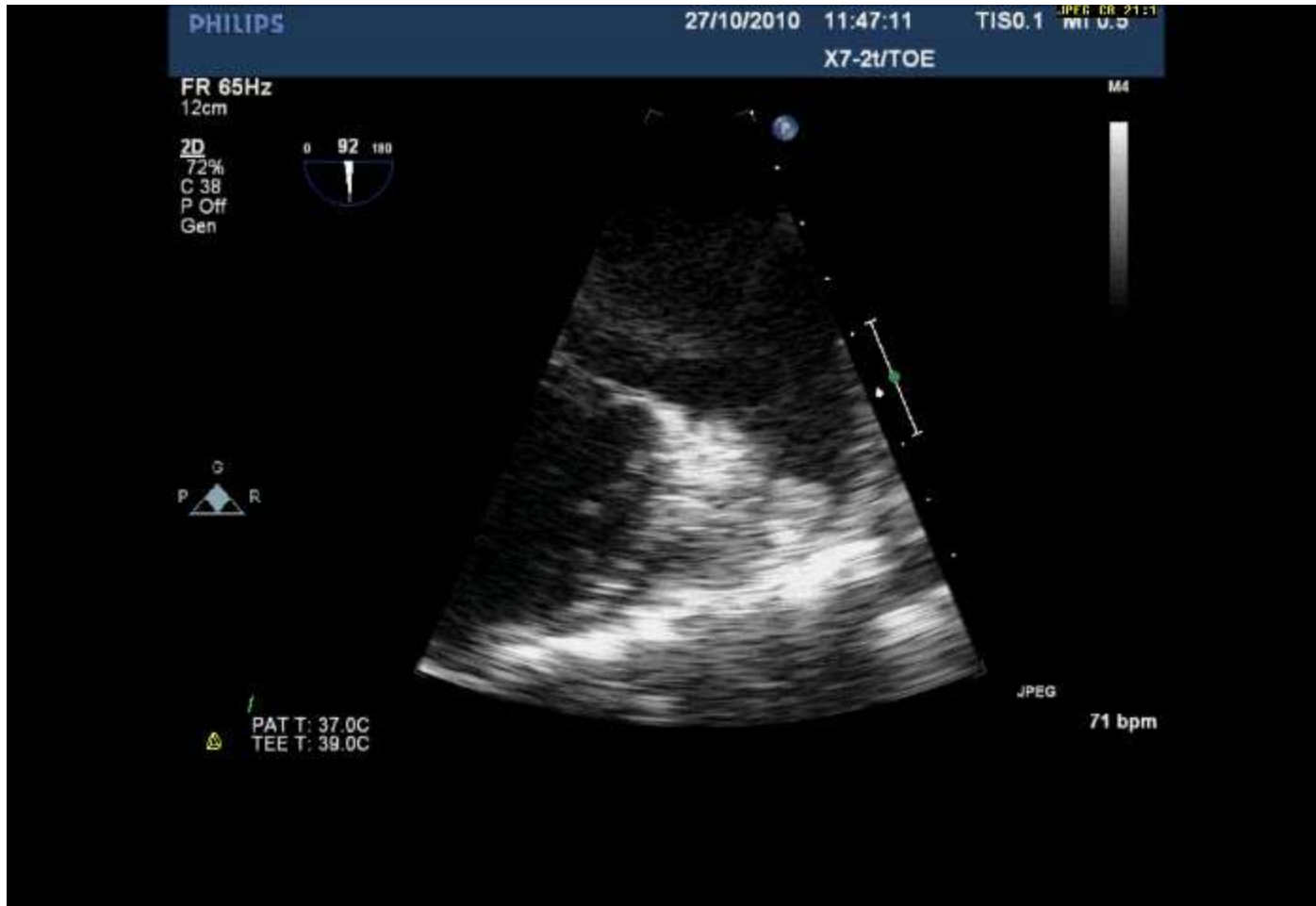# Understand the anatomy



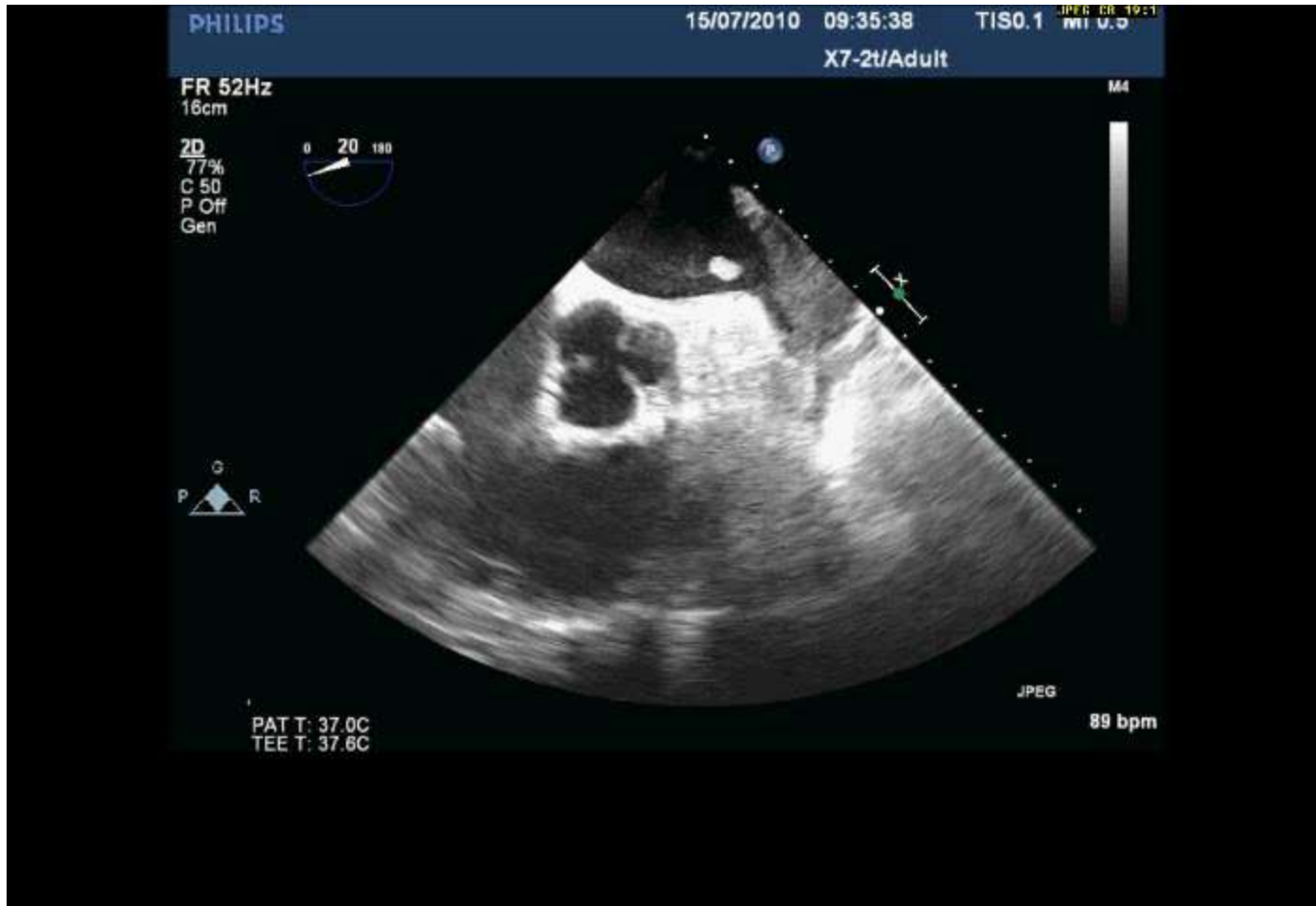
# Use multiple 2D planes



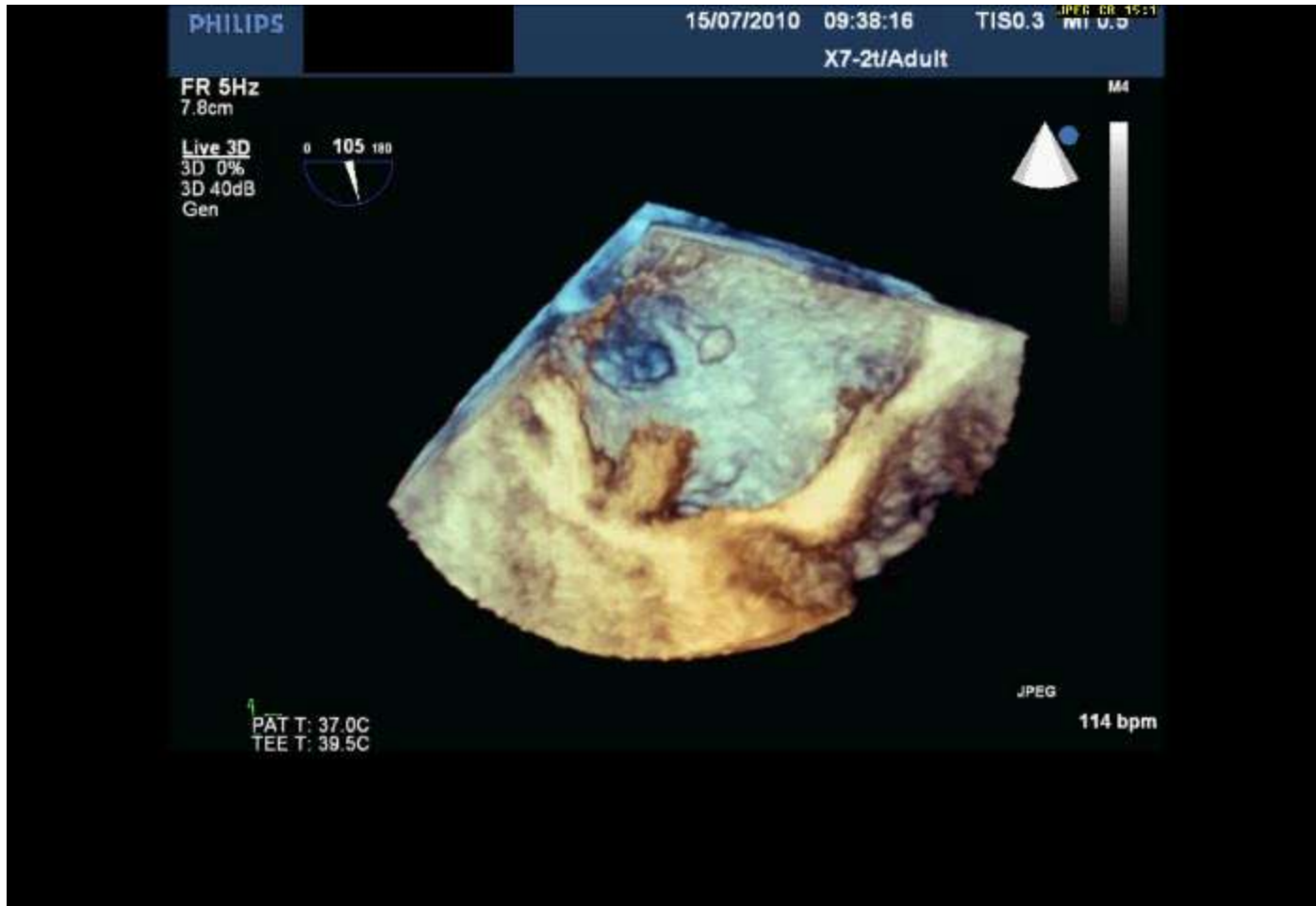# Exclude thrombus



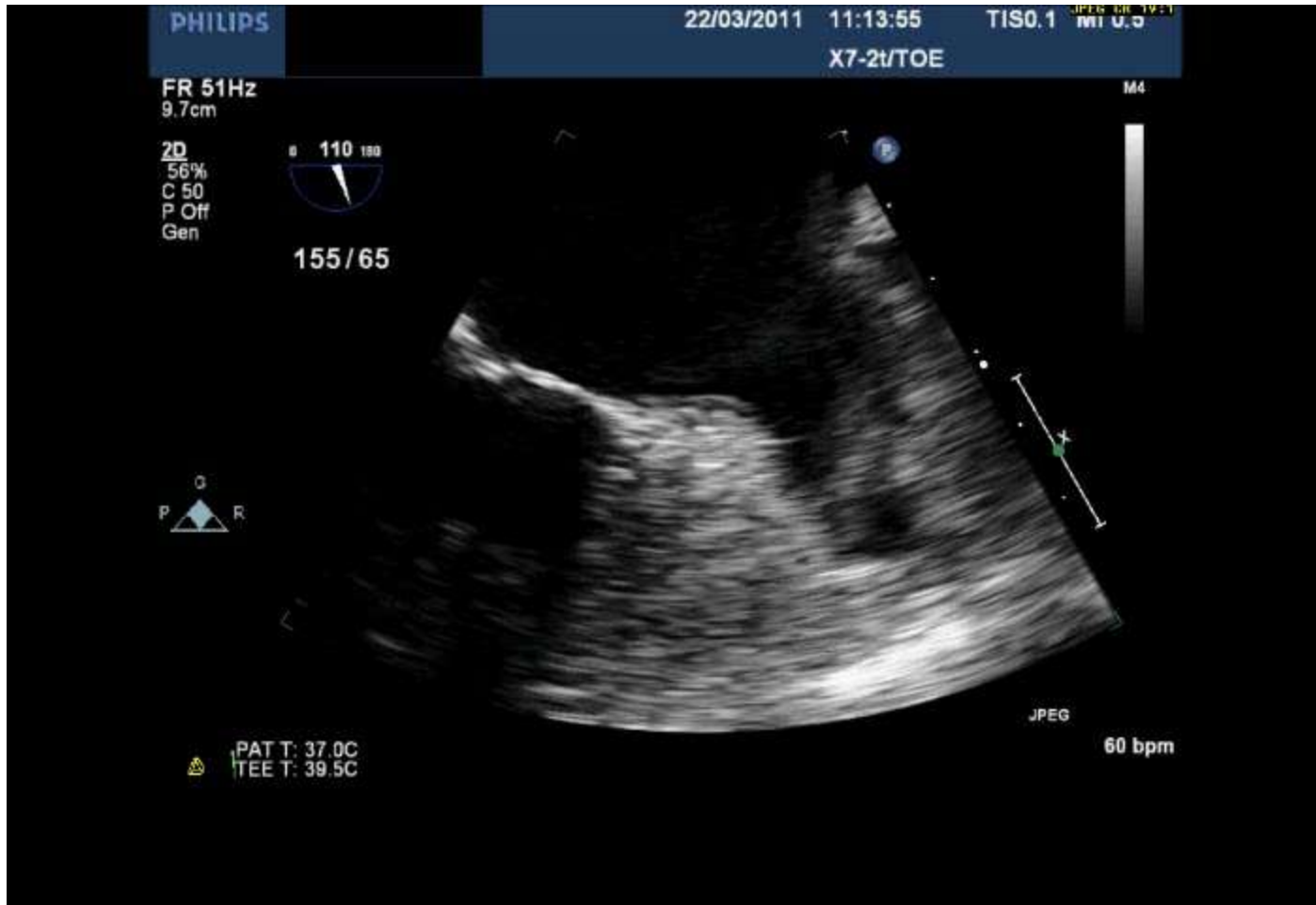# Exclude thrombus



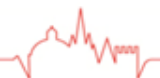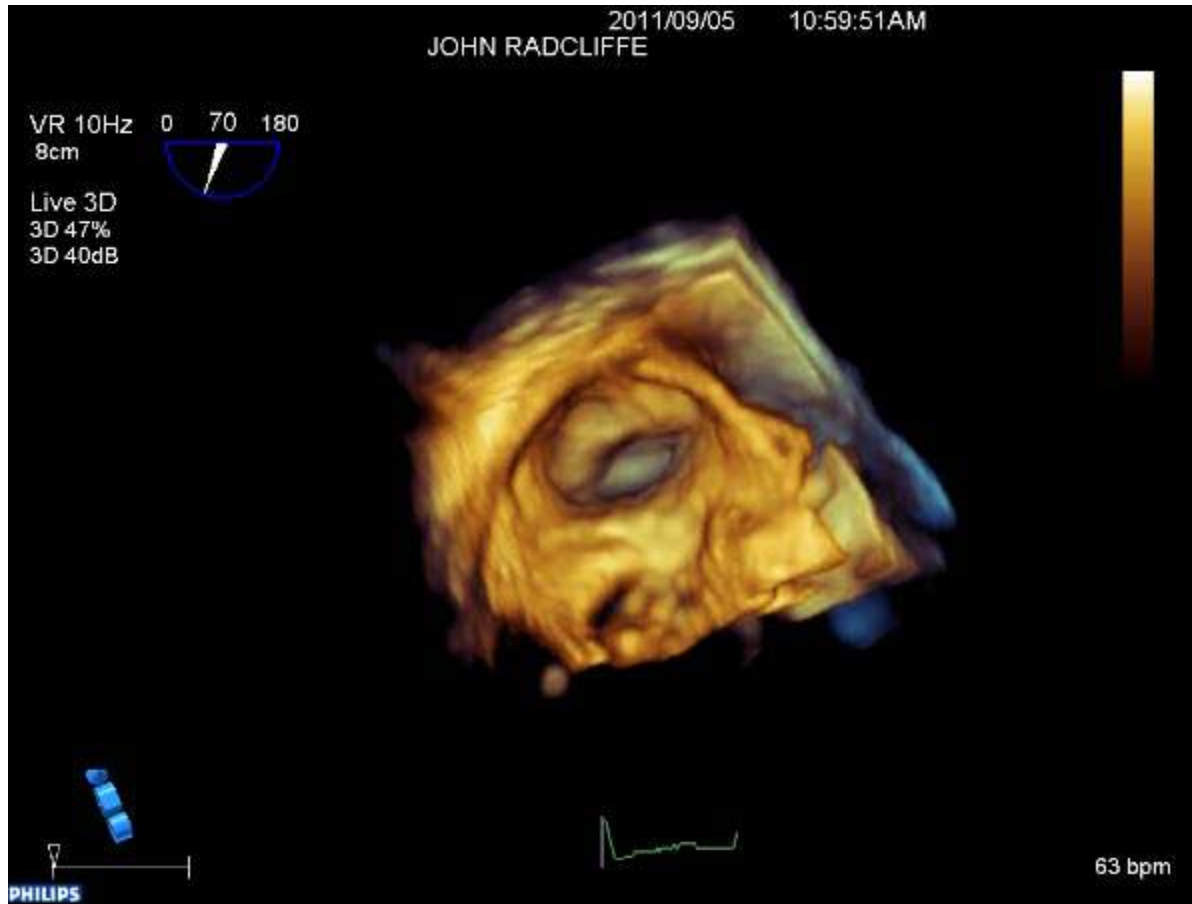
# Exclude thrombus



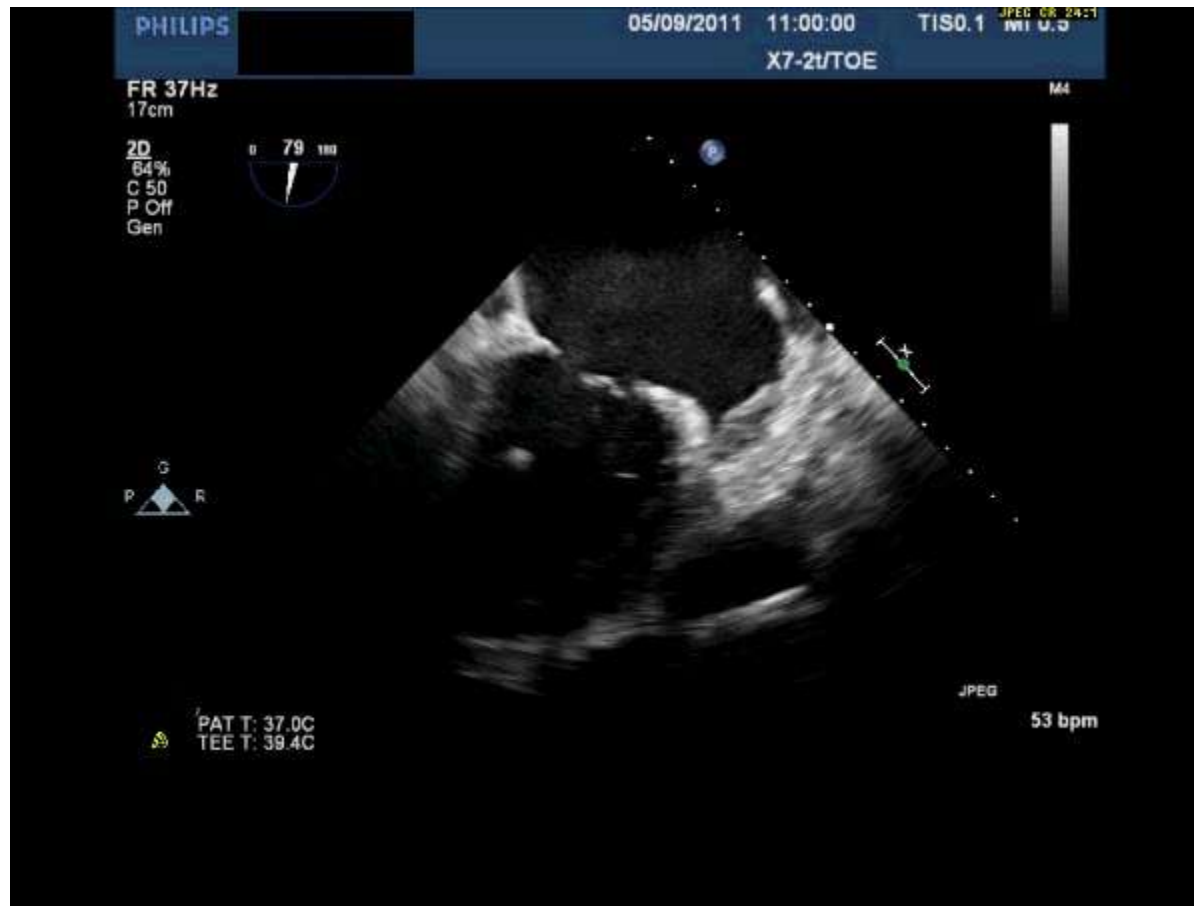# Exclude thrombus



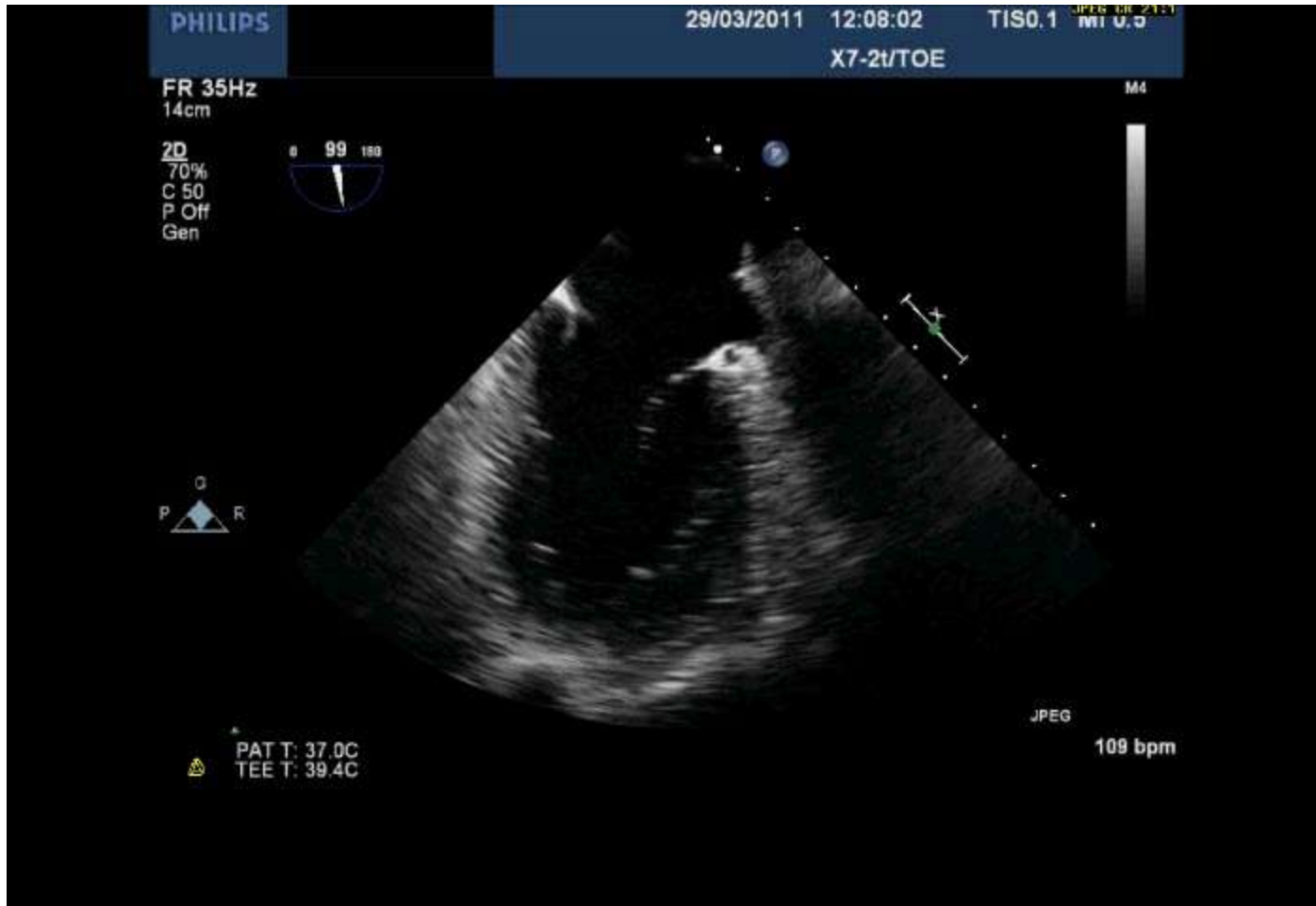
# Exclude thrombus



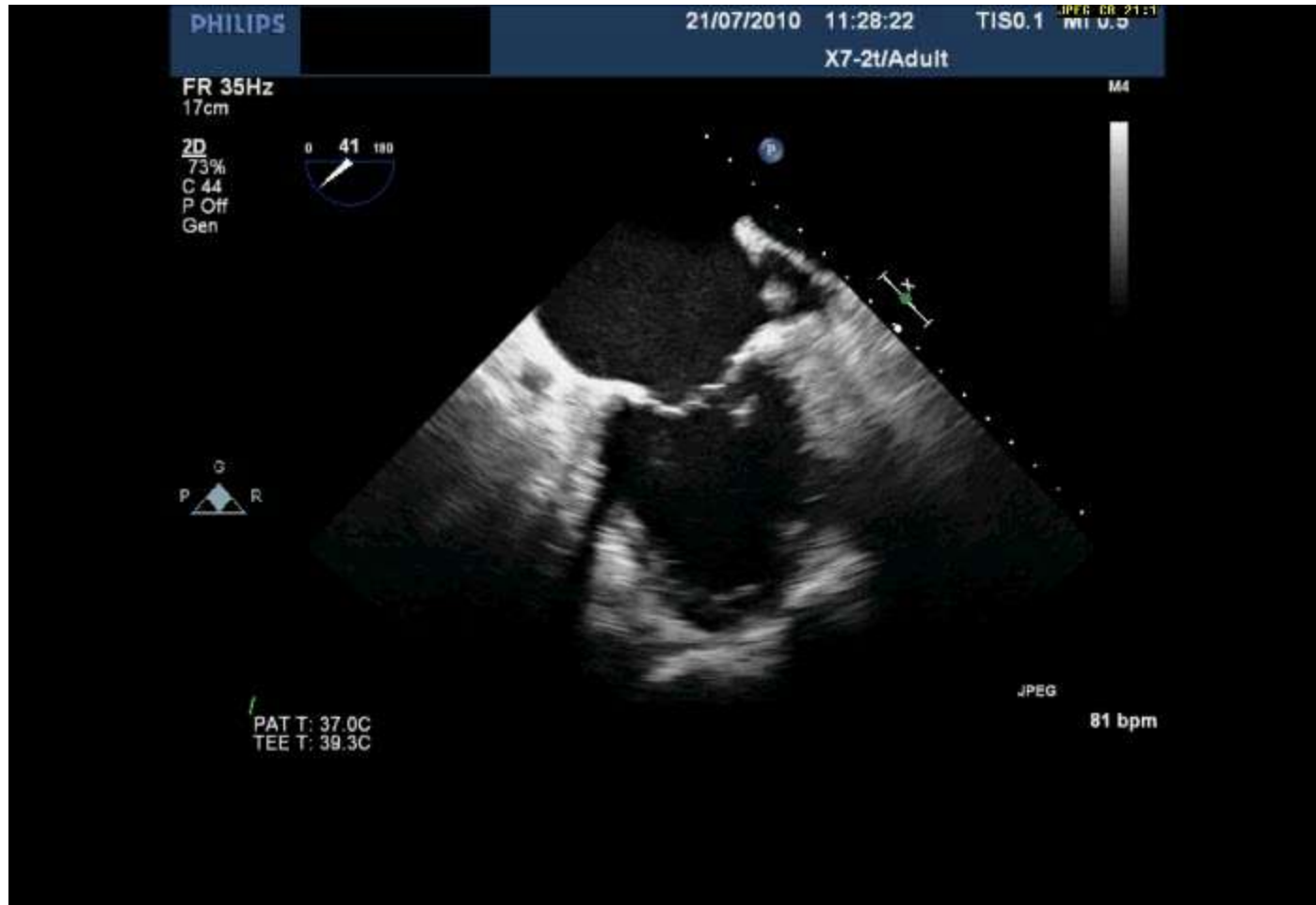# Exclude thrombus



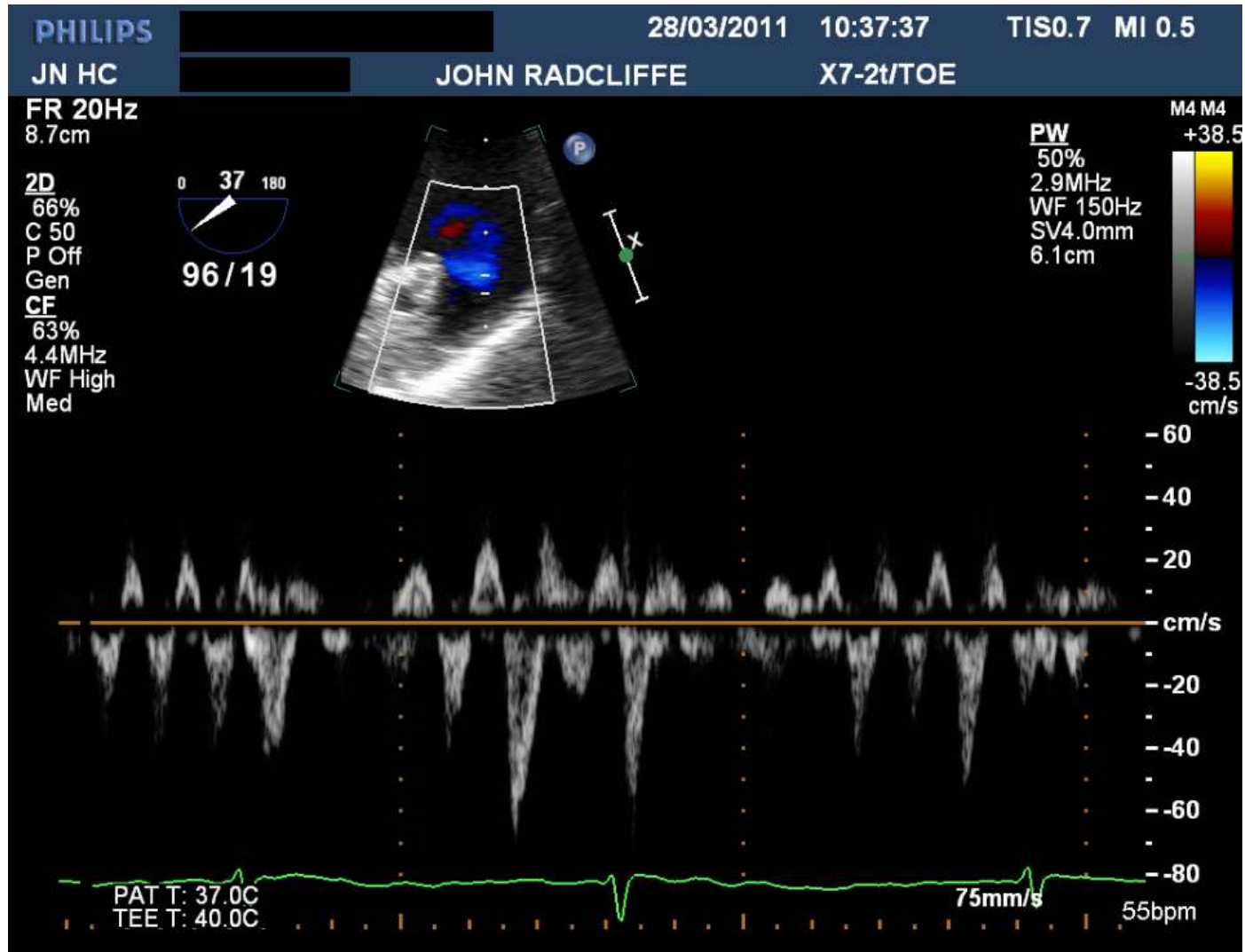
# Exclude thrombus



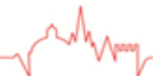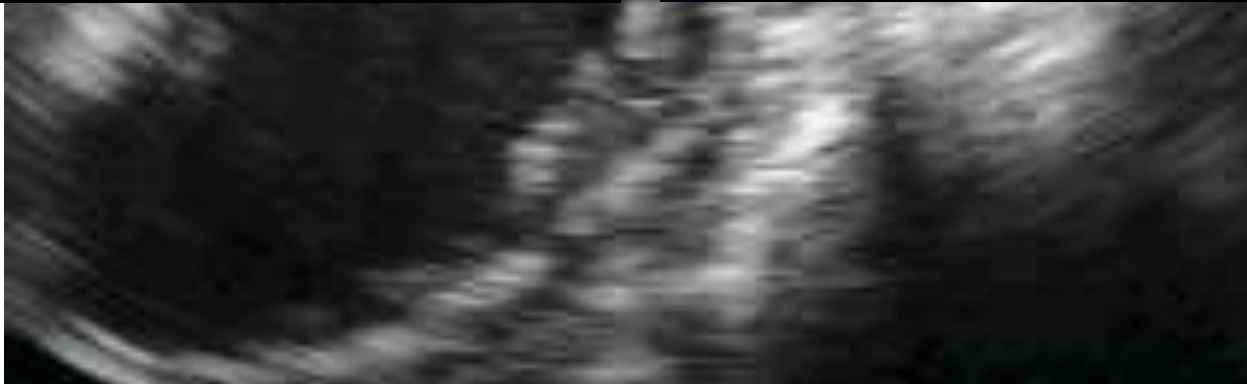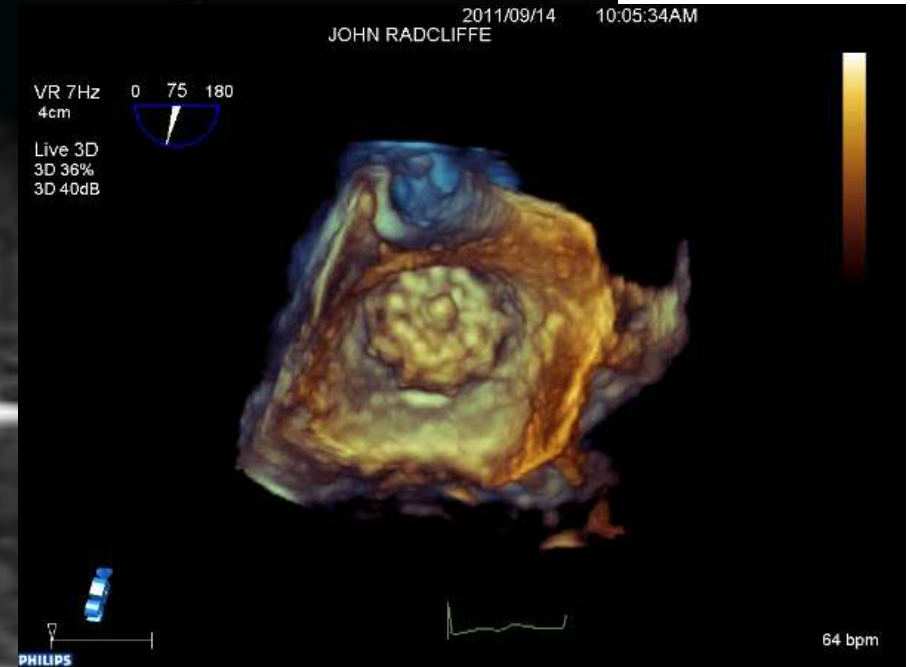
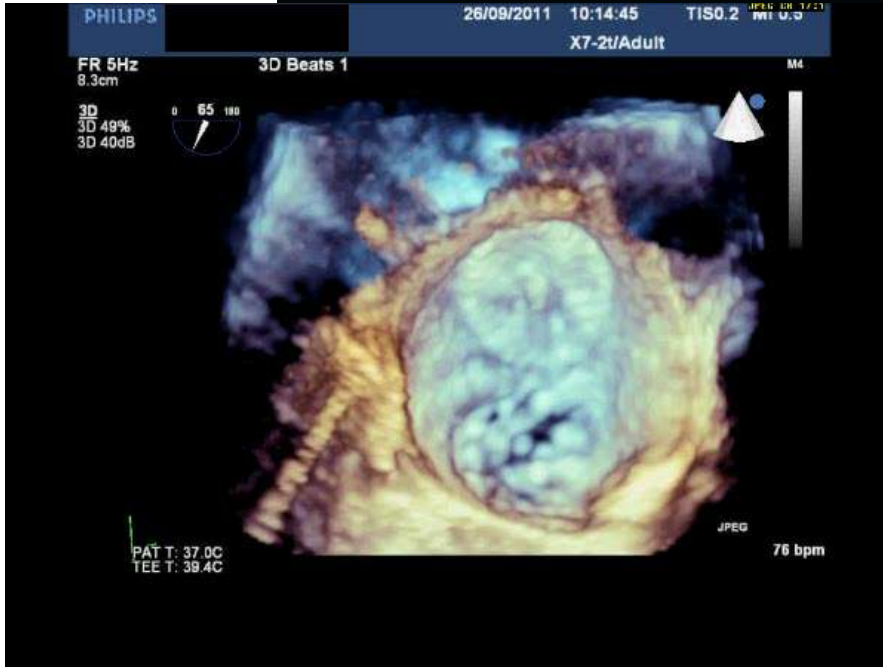# Exclude thrombus



# Exclude thrombus



# Device selection and size



# Devices available

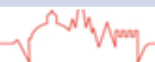	ACP	Watchman
Device concept	Lid	Plug
Device size range	16 – 30mm	21 – 33m
LAA size range	12.6 – 28.5mm	17 – 31mm
Sheath range	9F – 13F	12F
Min working depth	10mm	Device size
Retrieve before release?	Yes	Yes
Stability check	Shape and tug test	Compressed size



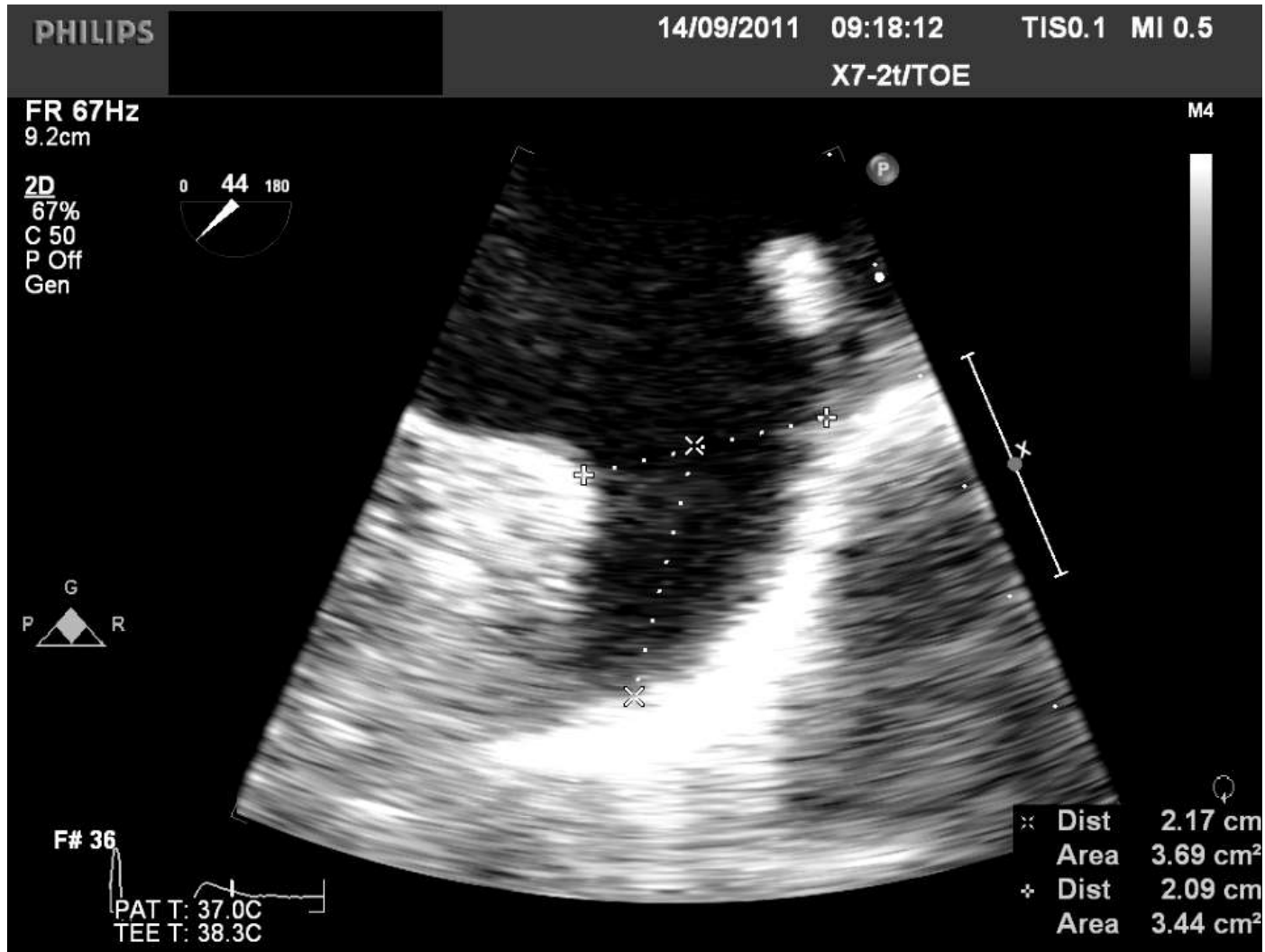
# Device sizing

Max LAA width (mm)	ACP size (mm)	Min depth (mm)
12.6 – 14.5	16	10
14.6 – 16.5	18	10
16.6 – 18.5	20	10
18.6 – 20.5	22	10
20.6 – 22.5	24	10
22.6 – 24.5	26	10
24.6 – 26.5	28	10
26.6 – 28.5	30	10
29 – 31		10

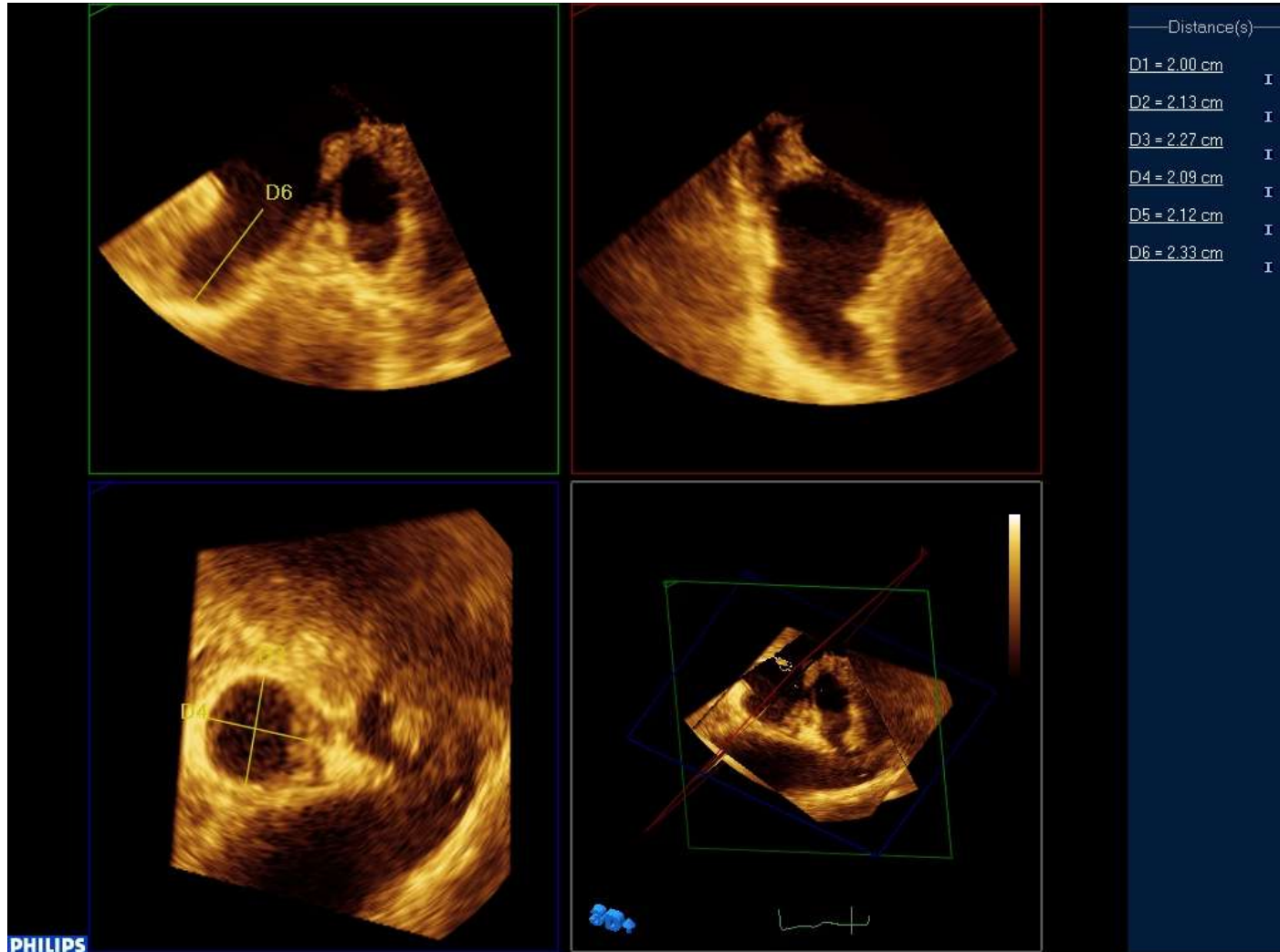
Max LAA width (mm)	Watchman size (mm)	Min depth (mm)
17 – 19	21	20.2
20 – 22	24	22.9
23 – 25	27	26.5
26 – 28	30	29.4
29 – 31	33	31.6



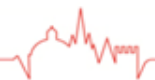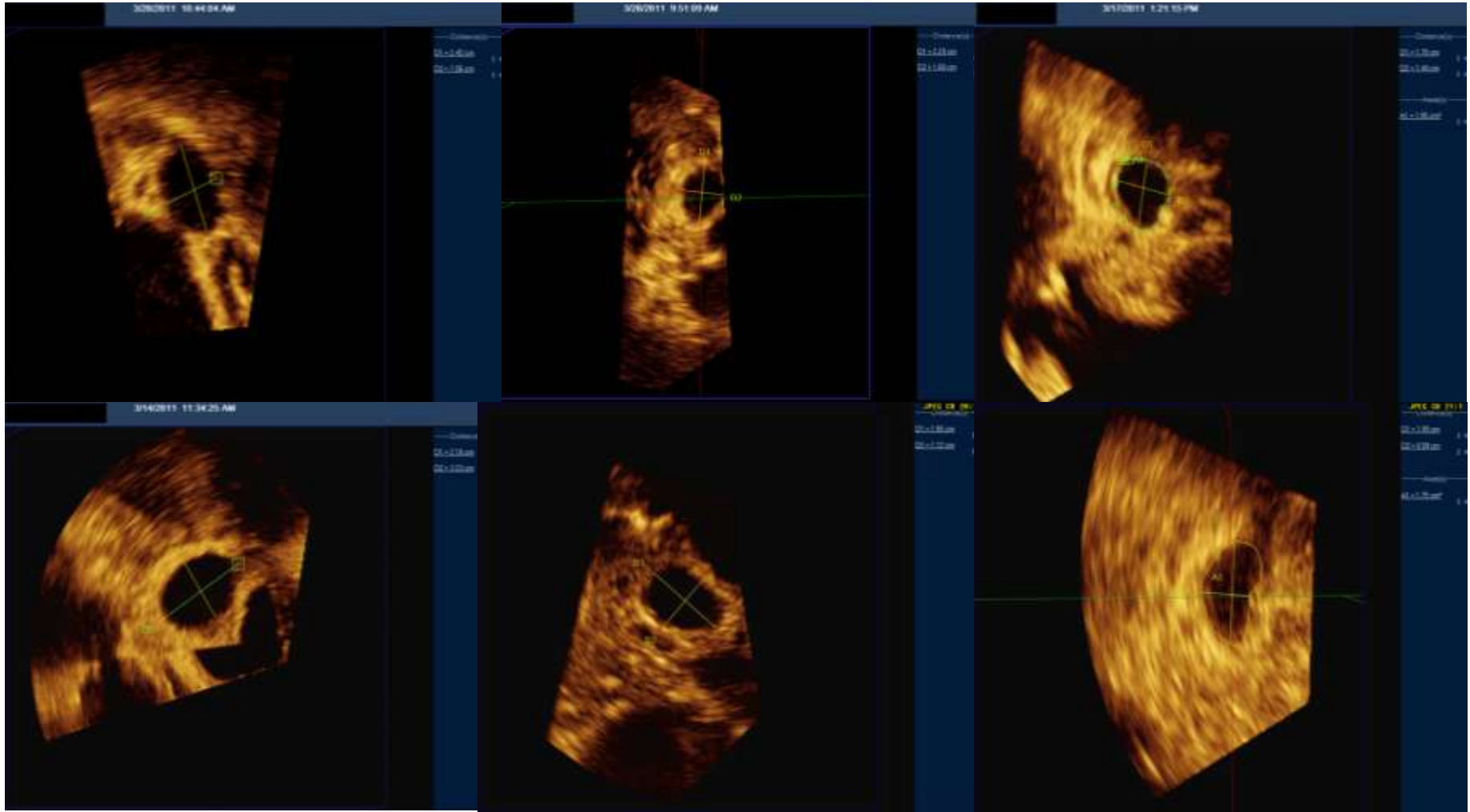
# Device selection and size



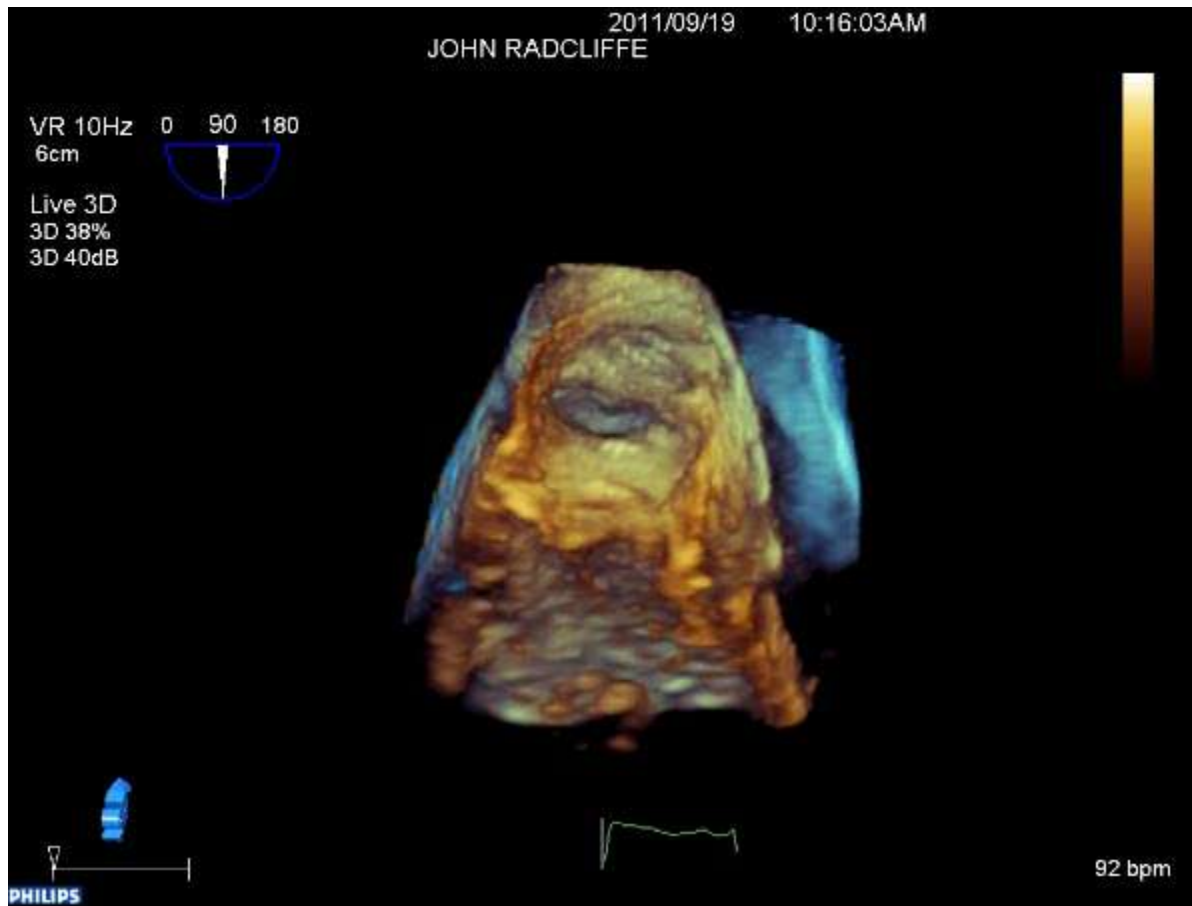
# Device selection and size



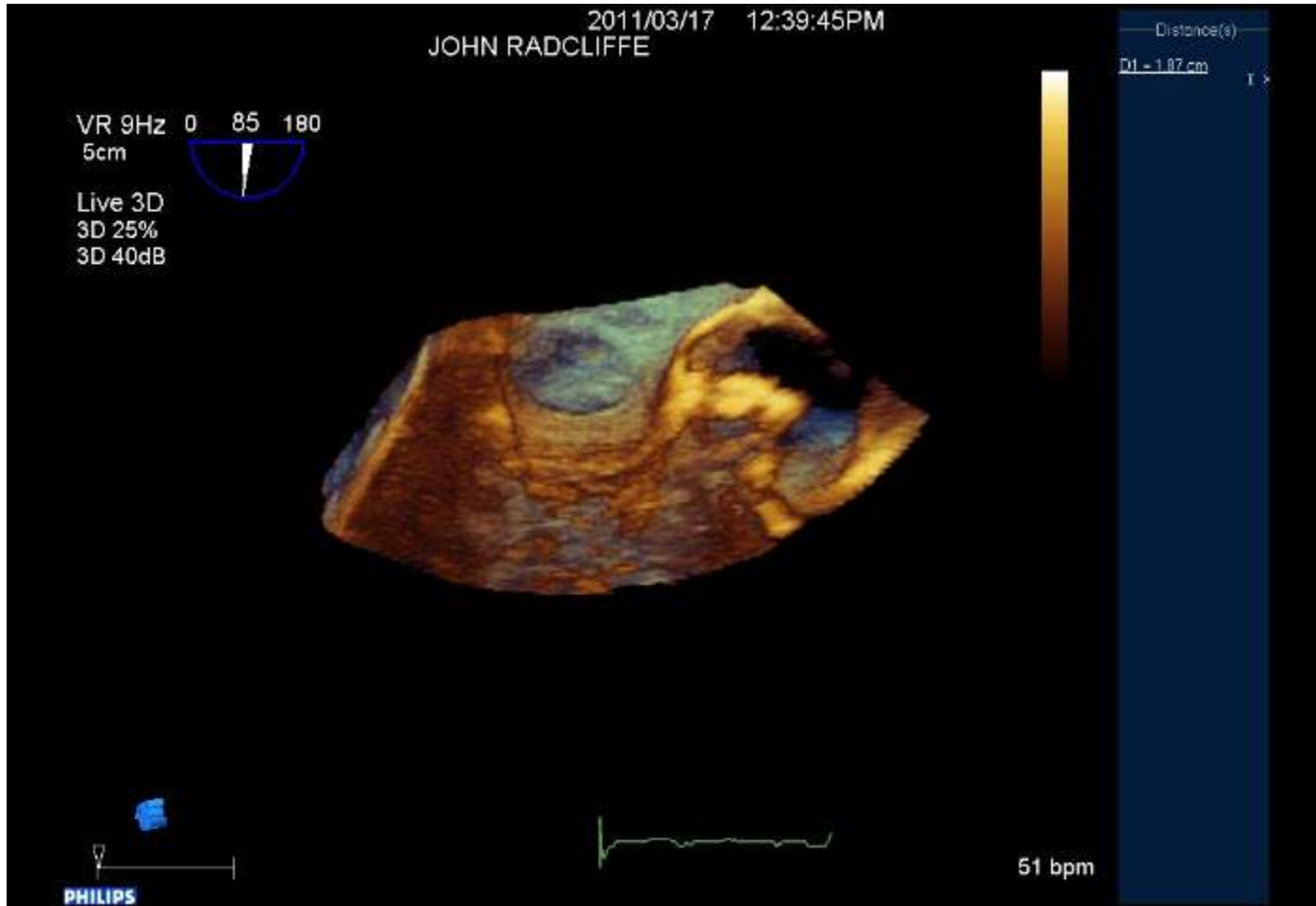
# Device selection and size



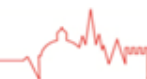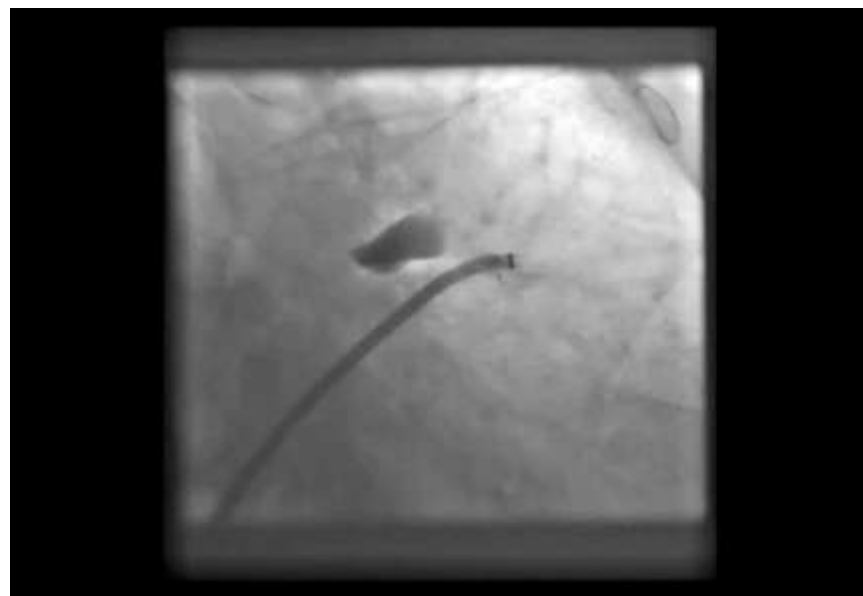
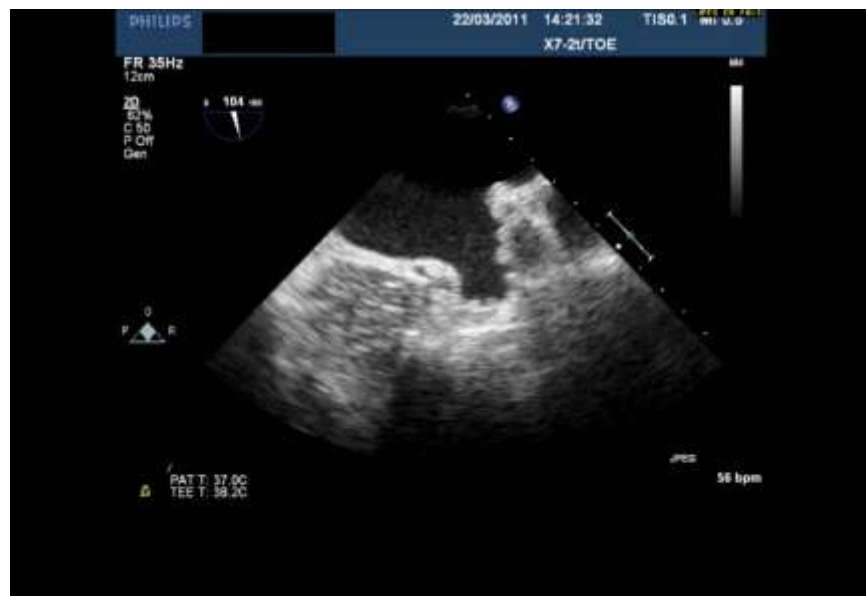# Device selection and size



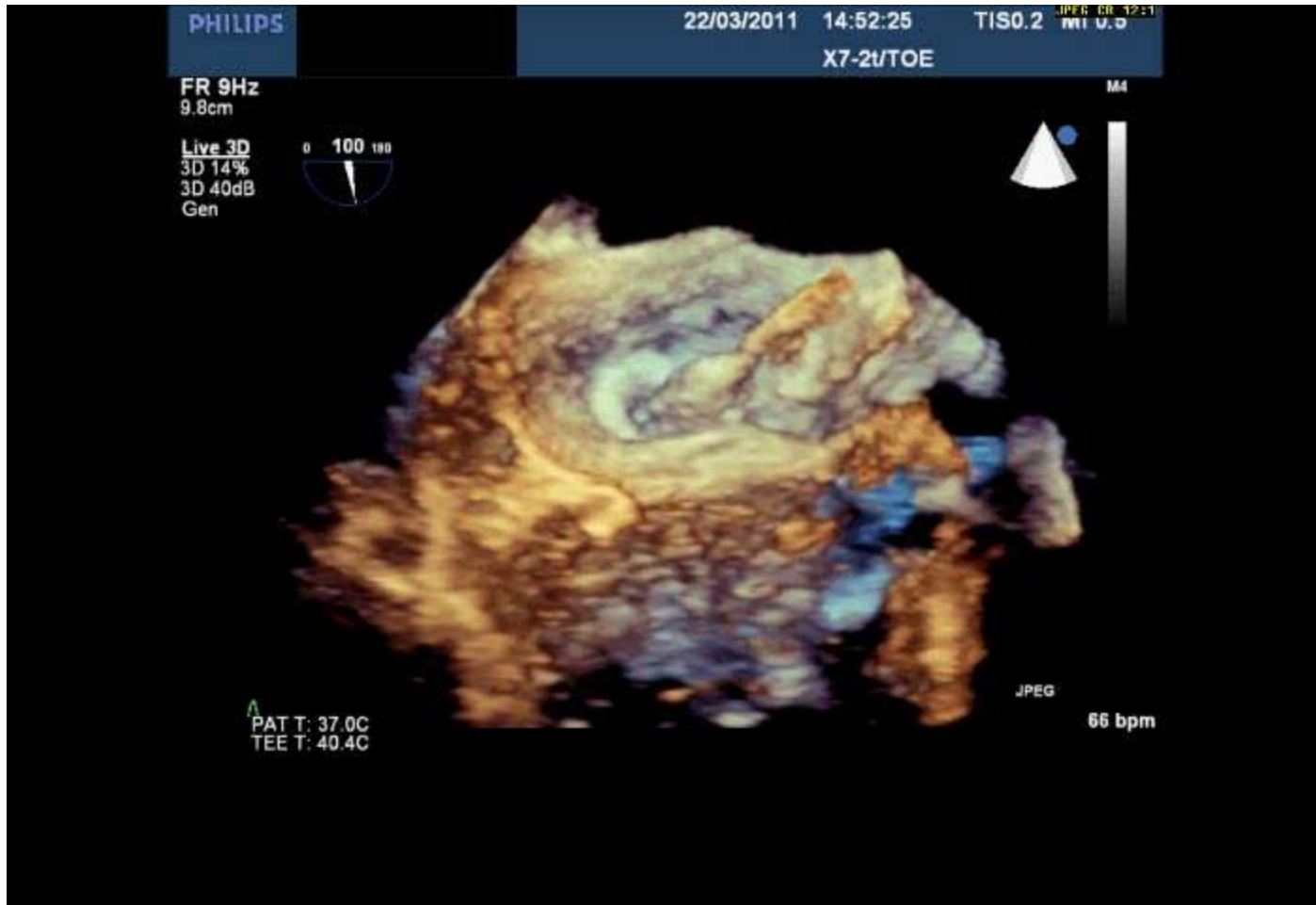
# Device selection and size



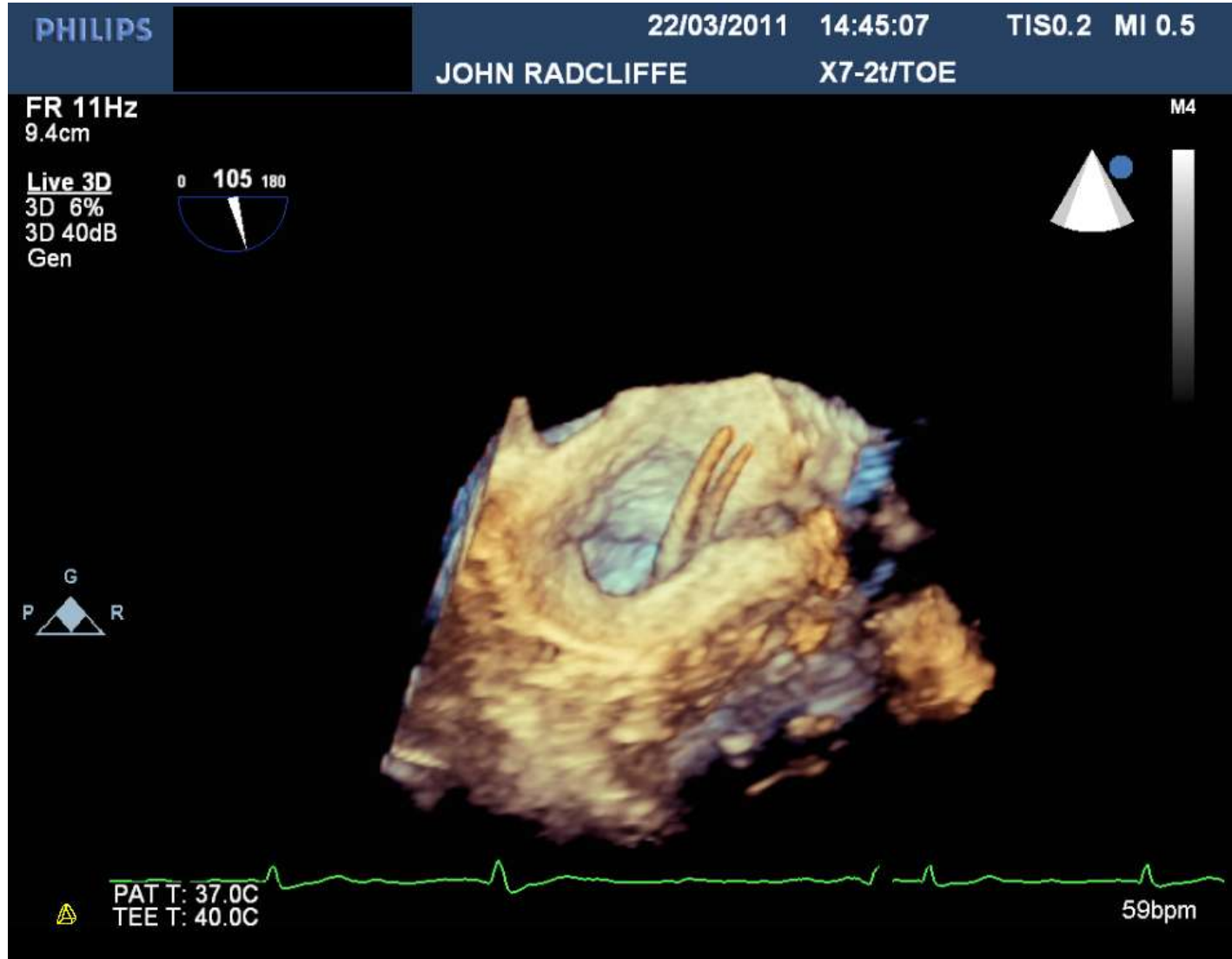
# Guide procedure



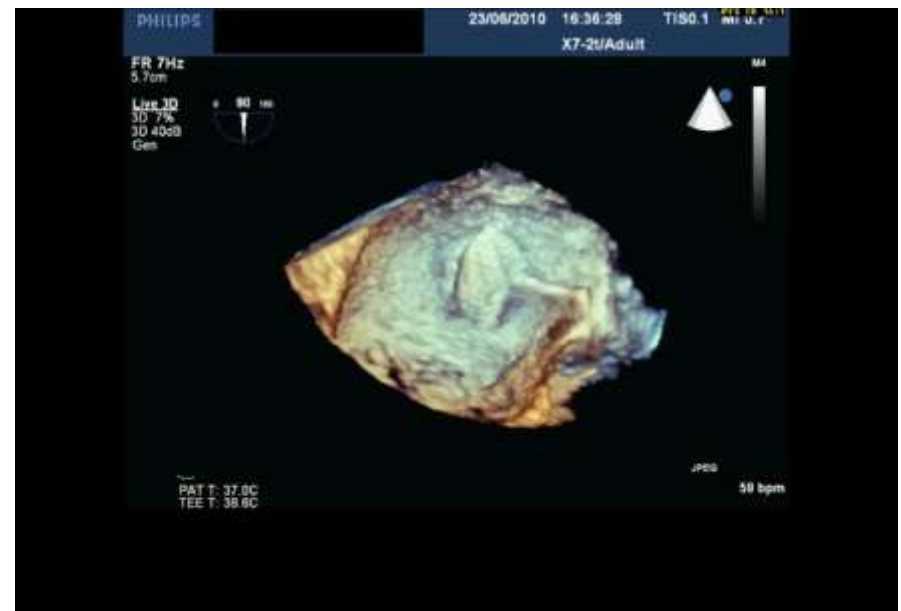
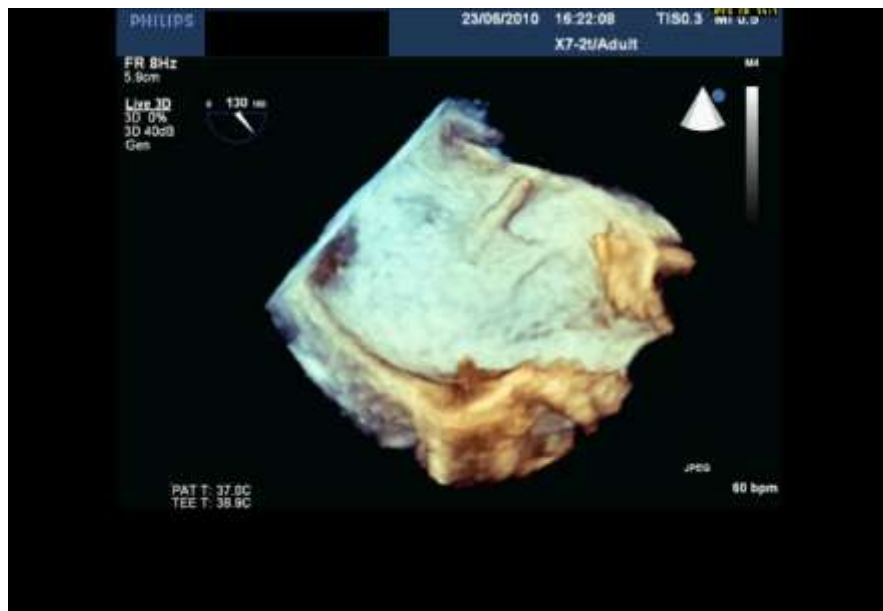
# Guide procedure



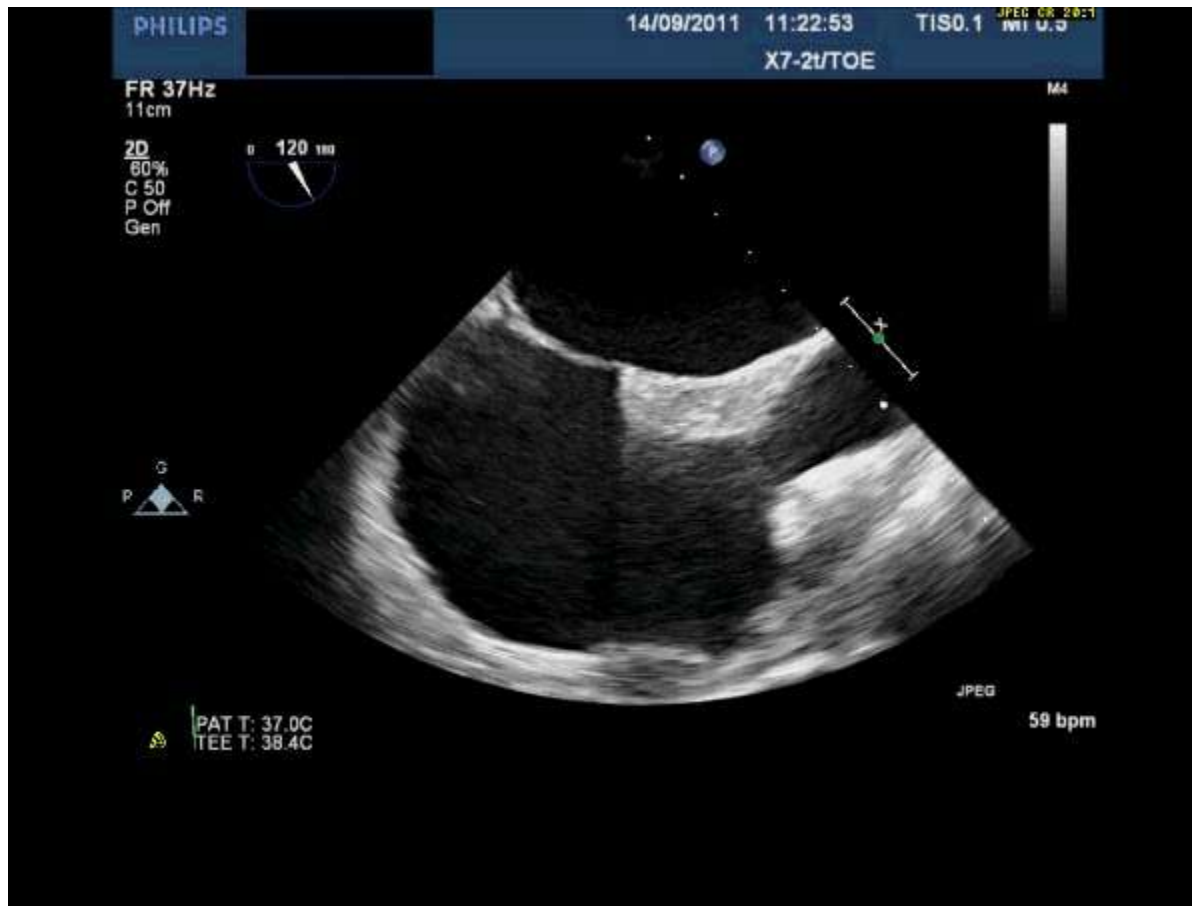# Guide procedure



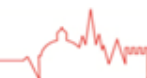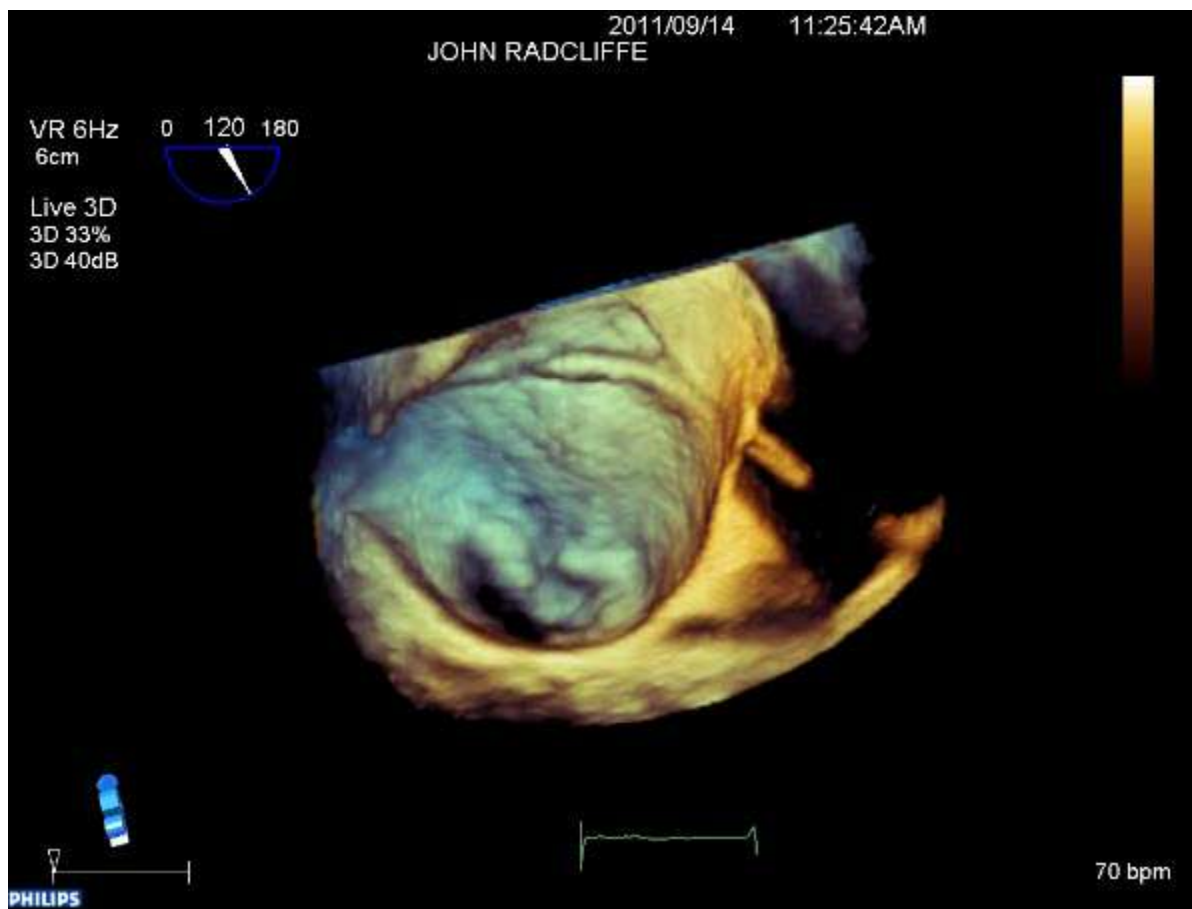# Guide procedure



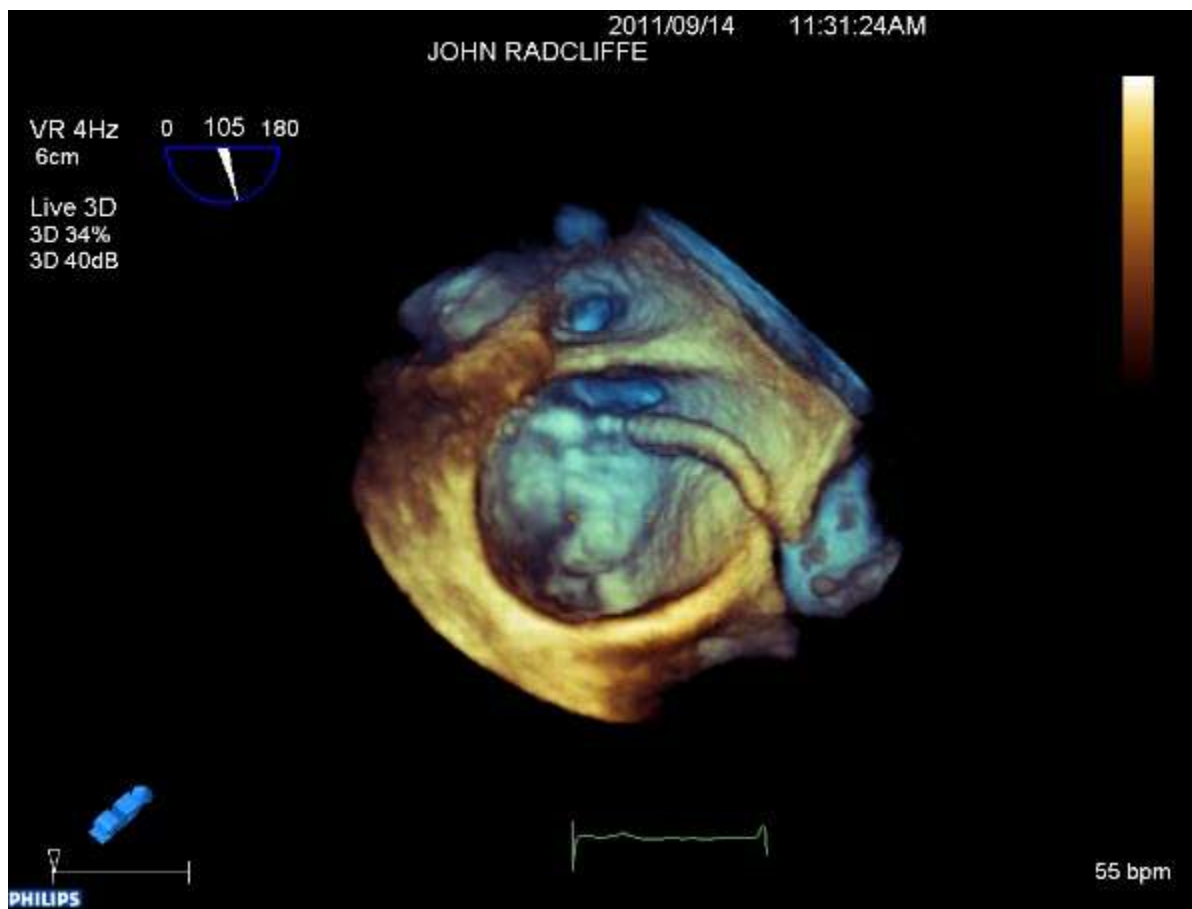
# Guide procedure



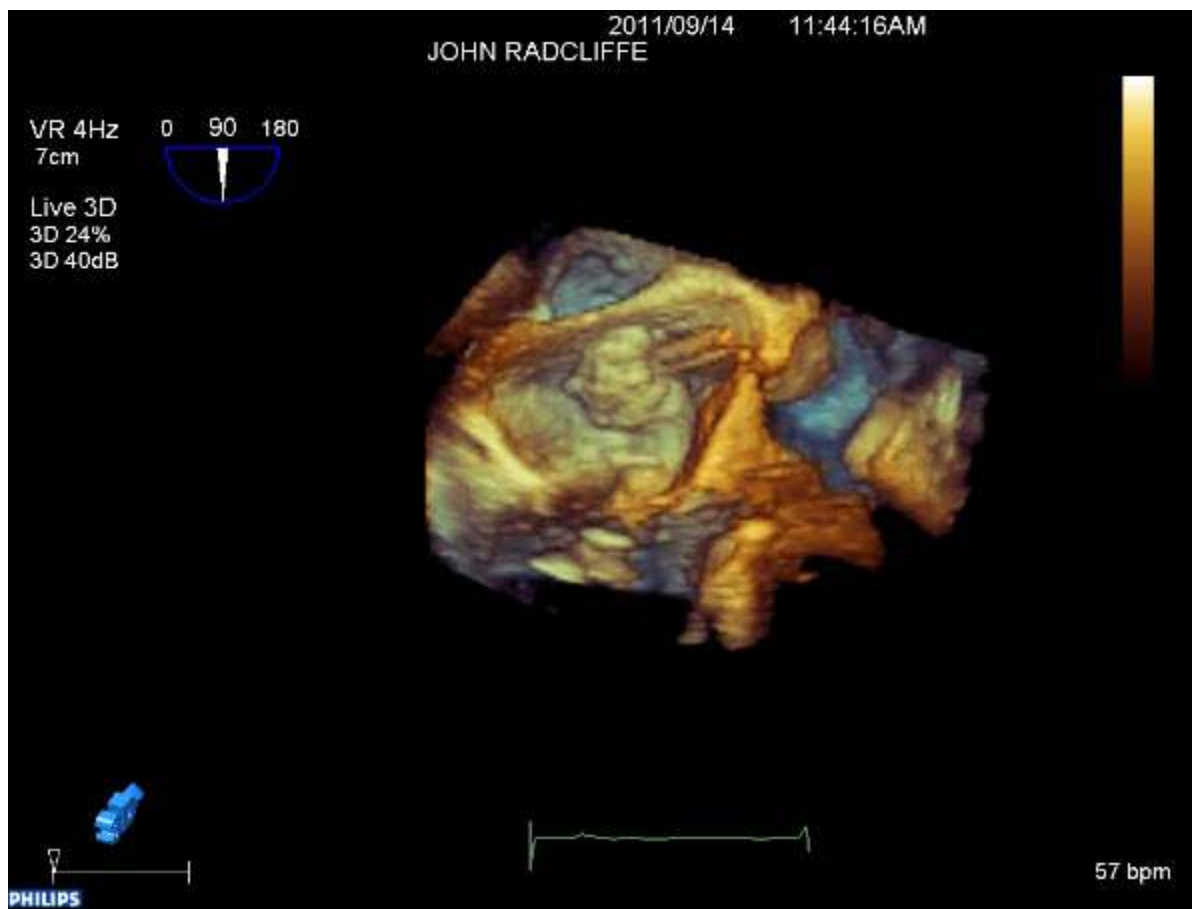
# Guide procedure



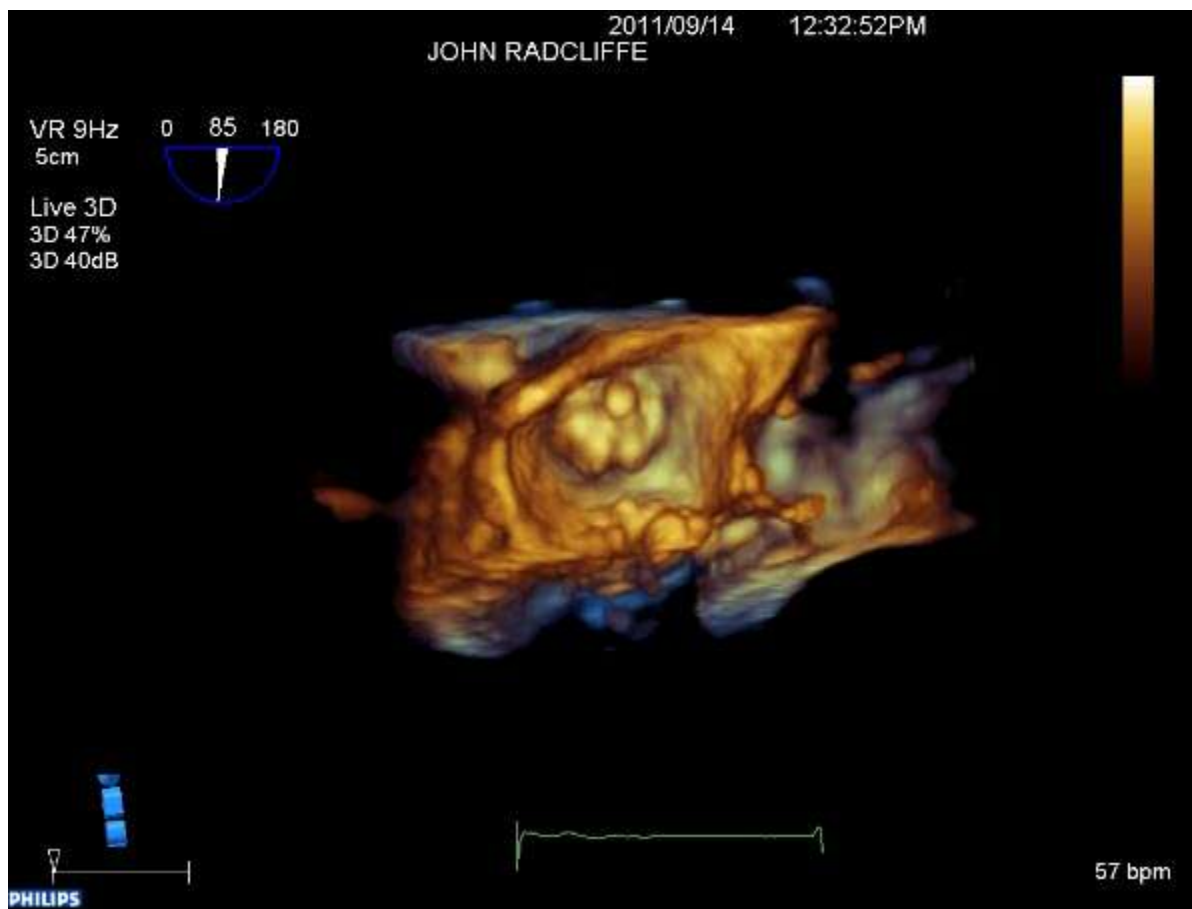
# Guide procedure



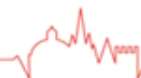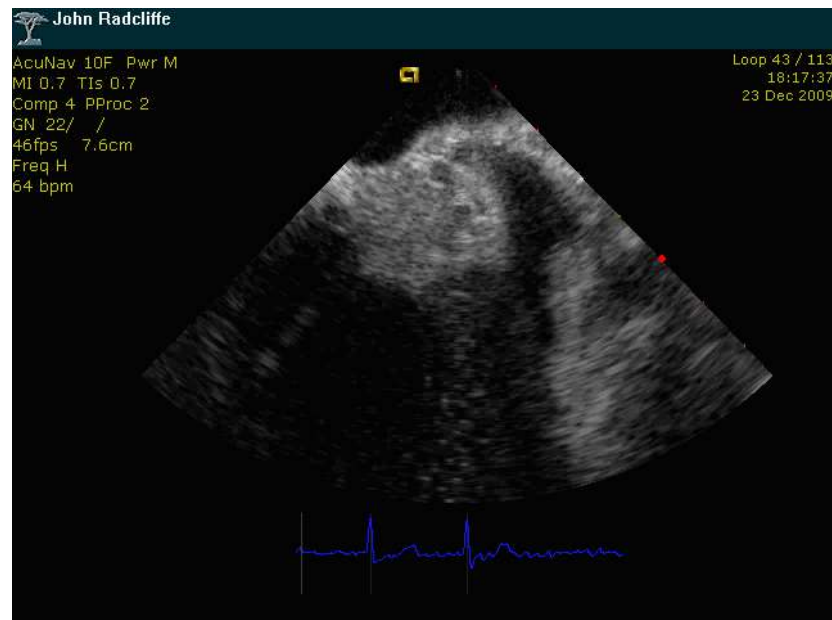
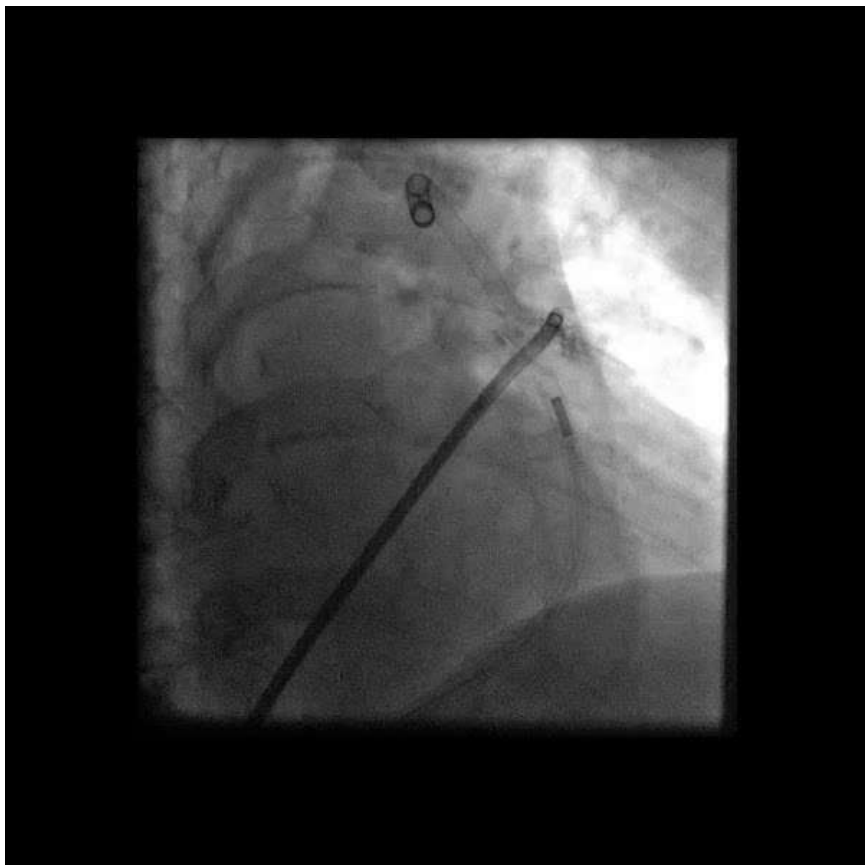
# Guide procedure



# Guide procedure



# Intracardiac echo



# Summary

- TOE ideal for assessment of LAA anatomy if performed diligently
- Best imaging modality to exclude thrombus
- 3D TOE adds to assessment, sizing and delivery
- Beware PFO...

