



Case MM

Dr Chris Pepper
Leeds Teaching Hospitals

- ▶ 60y.o. Male Professor of Surgery
 - ▶ Fit, active, mountaineer
 - ▶ 2007: Presented in acute pulmonary oedema
 - ▶ Acute severe mitral regurgitation
 - ▶ Normal coronary arteries
 - ▶ Good left ventricular function
- 

2007: Mitral valve replacement


- ▶ 3 ruptured chords arising from the posterior papillary muscle
 - ▶ Anterior mitral leaflet excised
 - ▶ Posterior leaflet preserved
 - ▶ Tissue mitral prosthesis inserted

 - ▶ Dual chamber permanent pacemaker for persistent bradycardia
- 

2008

- ▶ Persistent atrial fibrillation
 - ▶ DC cardioversion

 - ▶ Rx amiodarone 100mg od.

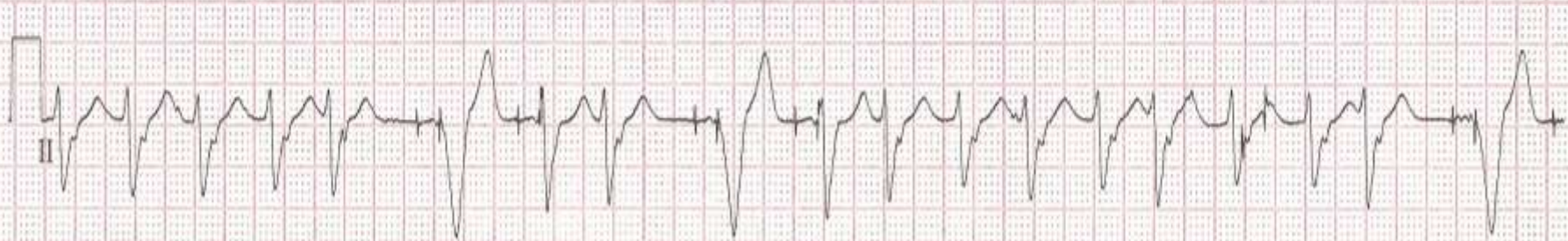
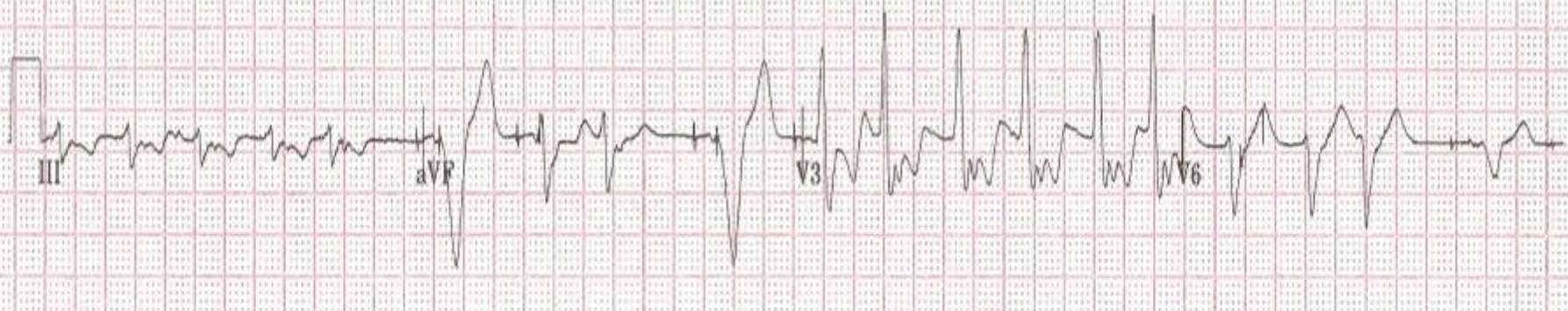
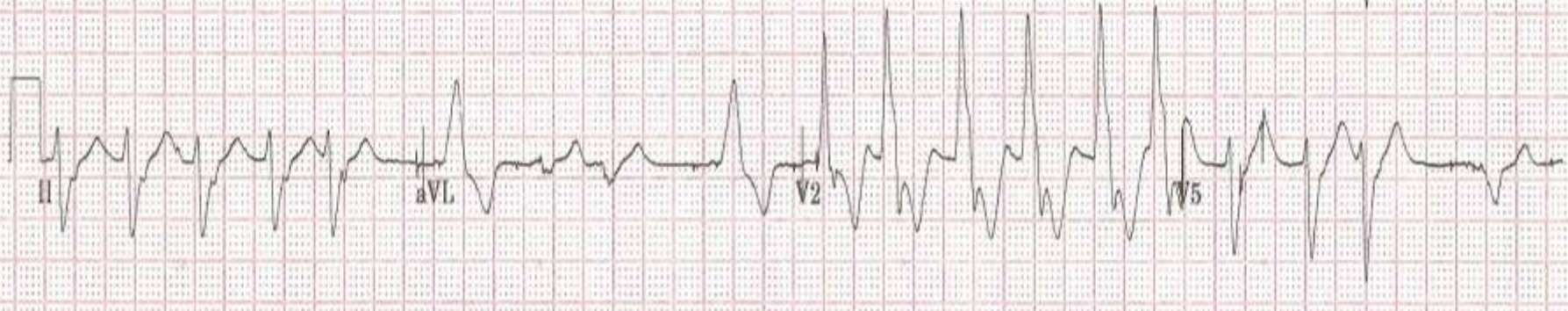
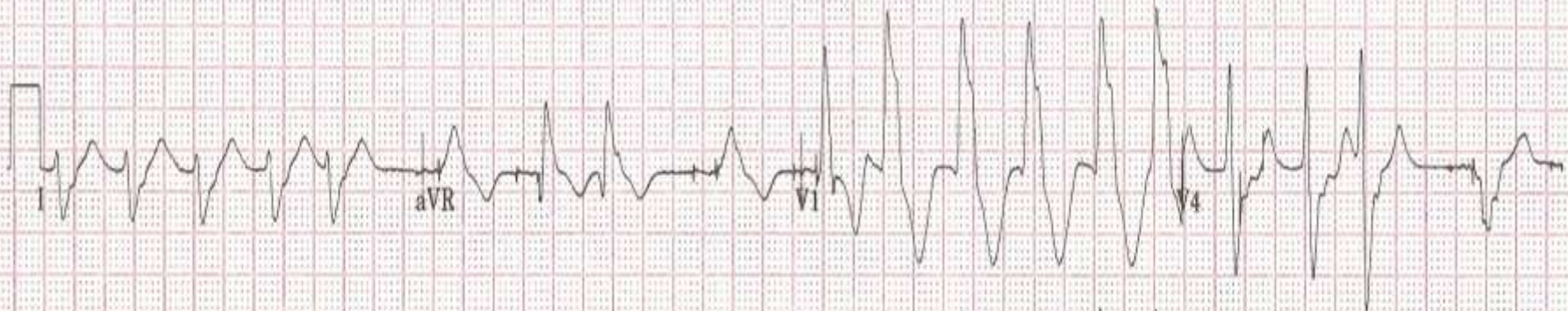
 - ▶ Echo: Good LV. Moderate anterior para-prosthetic mitral regurgitation
- 

June 2009


- ▶ Atrial pacing lead failure
- ▶ Both leads extracted
 - Difficult procedure – densely adherent leads
 - Replacement device

July 2009


- ▶ Recurrent dizziness and dyspnoea while operating

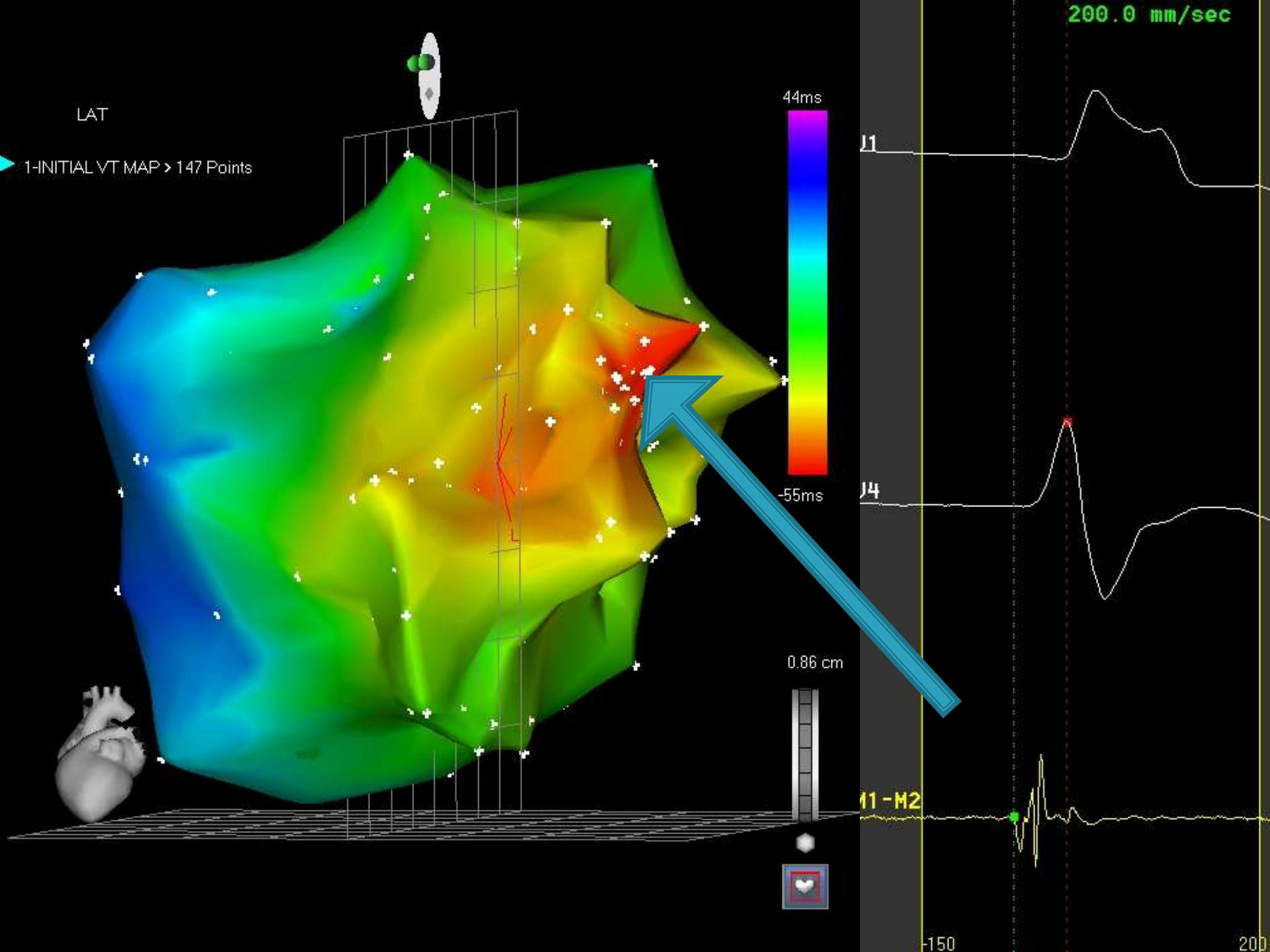


- ▶ Admitted
 - ▶ Echocardiogram: no change
 - ▶ Biochemistry normal
 - ▶ Inflammatory markers normal

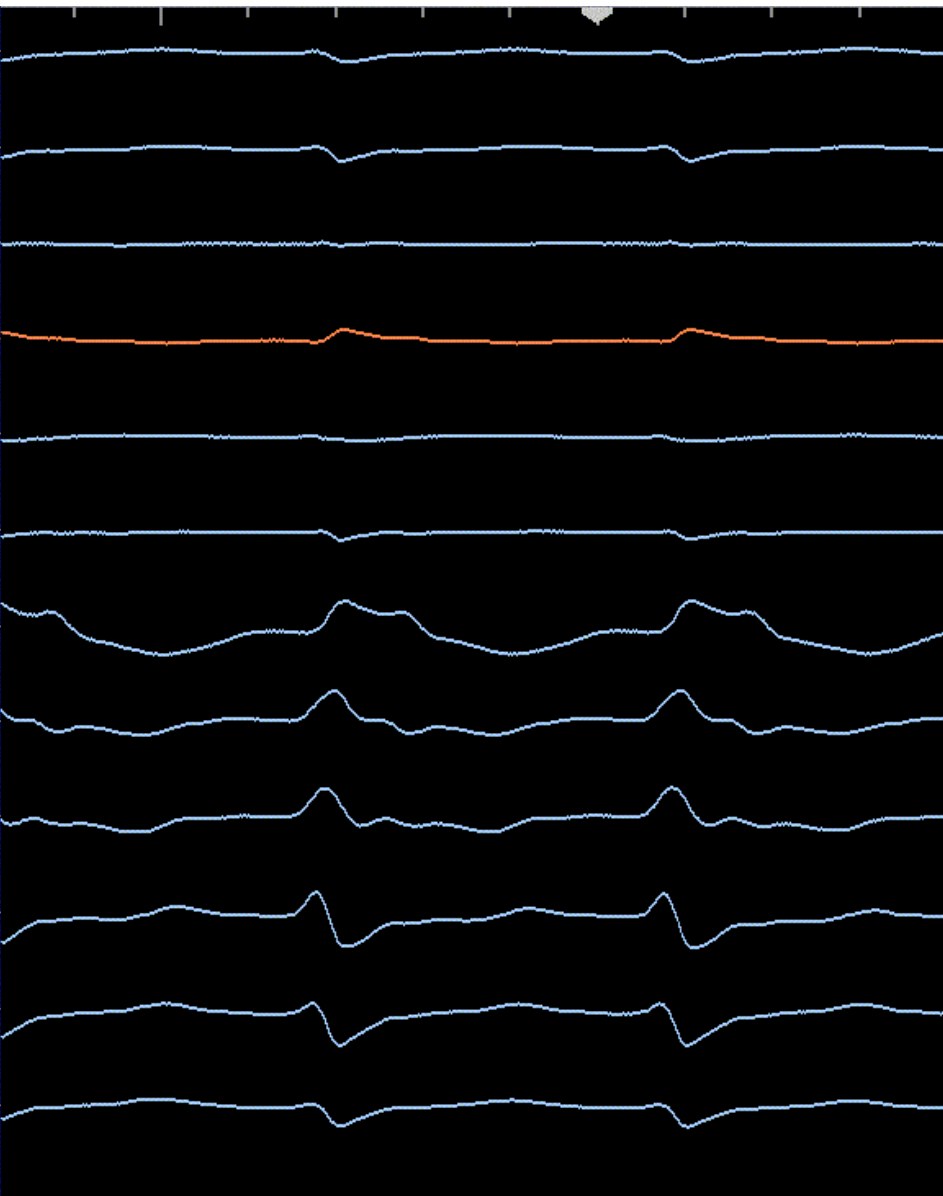
 - ▶ 24hrs iv amiodarone
 - Transiently settled
 - Self-discharged
 - Symptoms recurred 2 days later
- 

- ▶ Readmitted
 - ▶ Near incessant tachycardia
 - ▶ BP 90/60
 - ▶ Deteriorating LV function
 - ▶ Creatinine 170

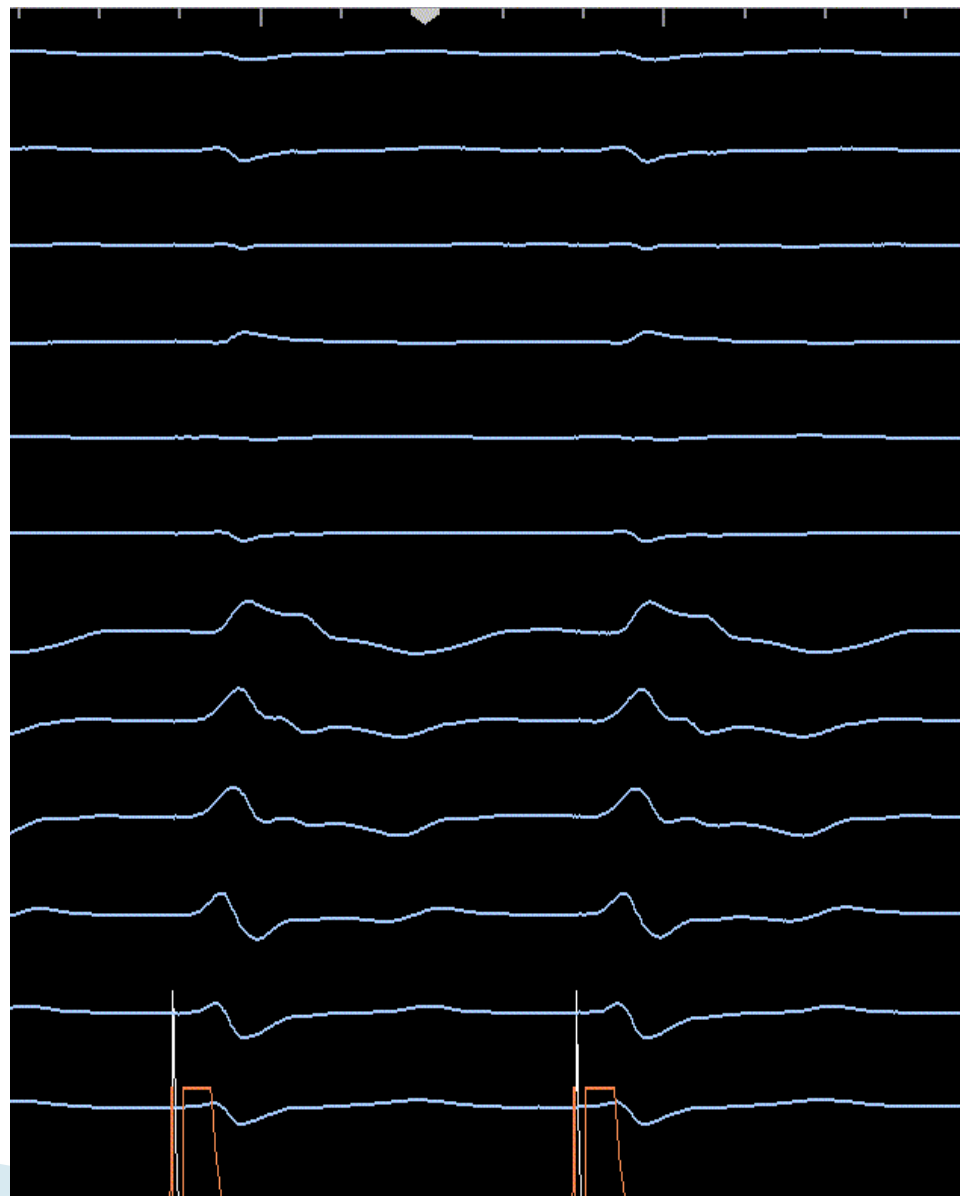
 - ▶ Taken to lab
- 

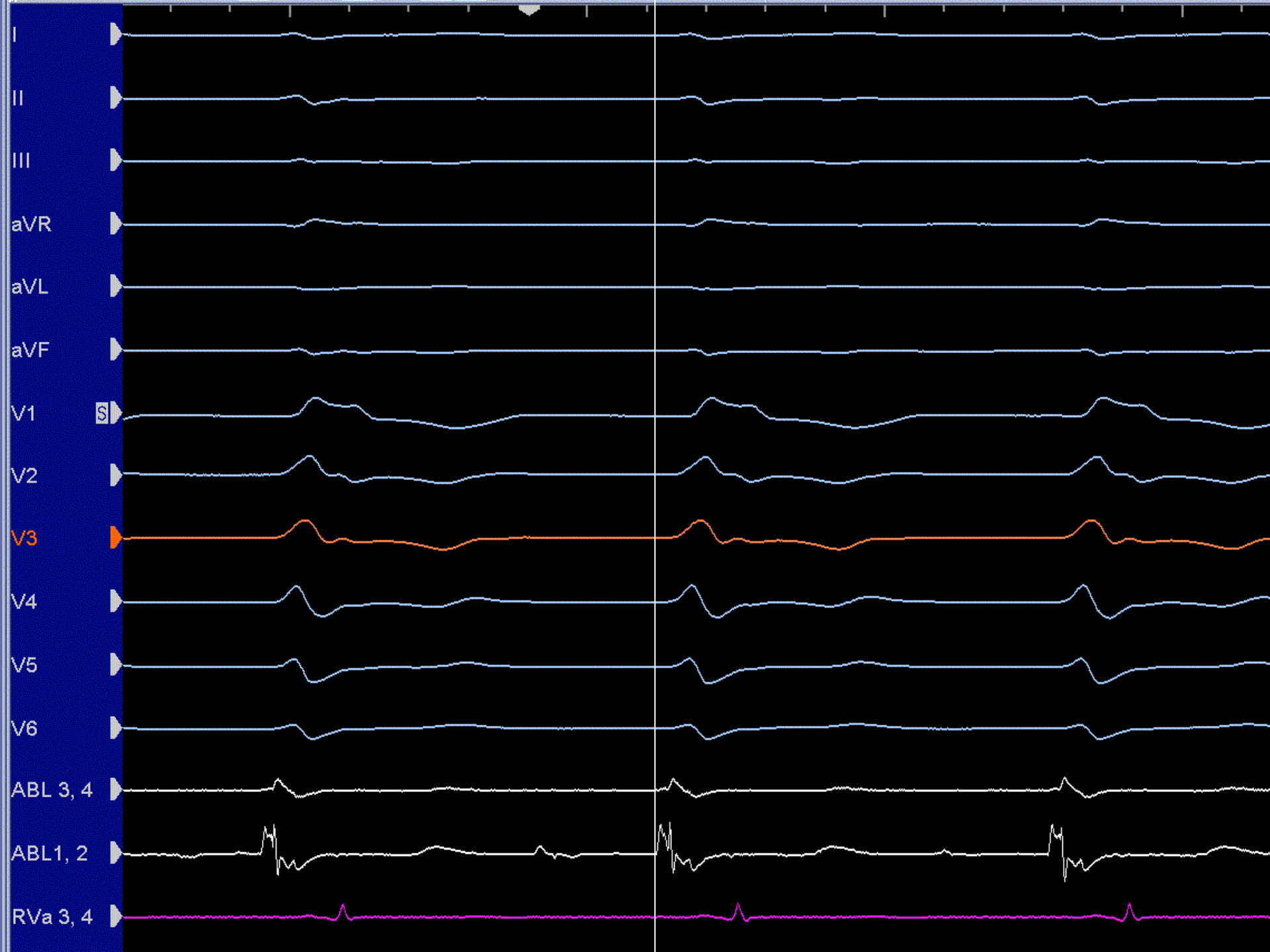


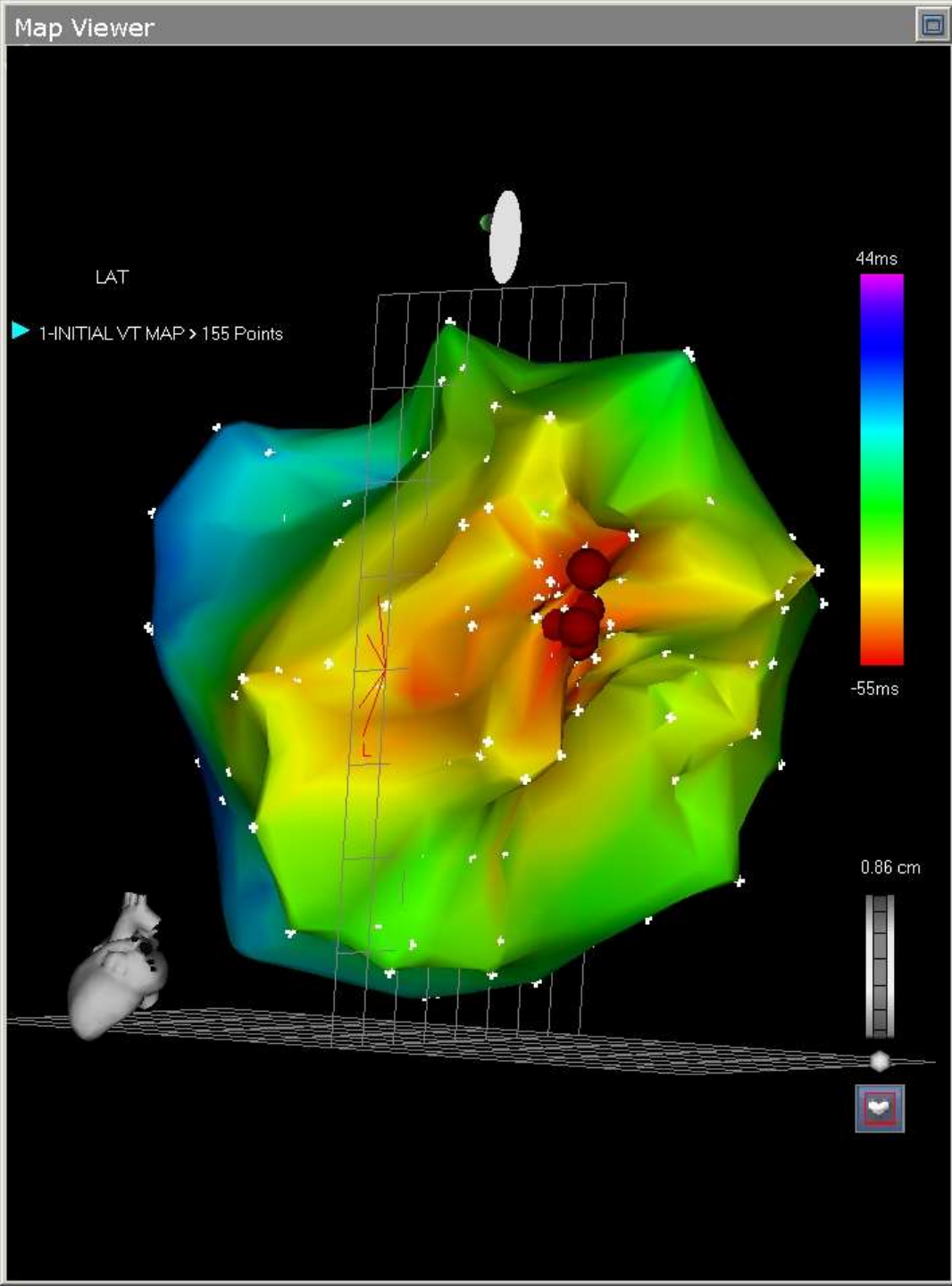
Template



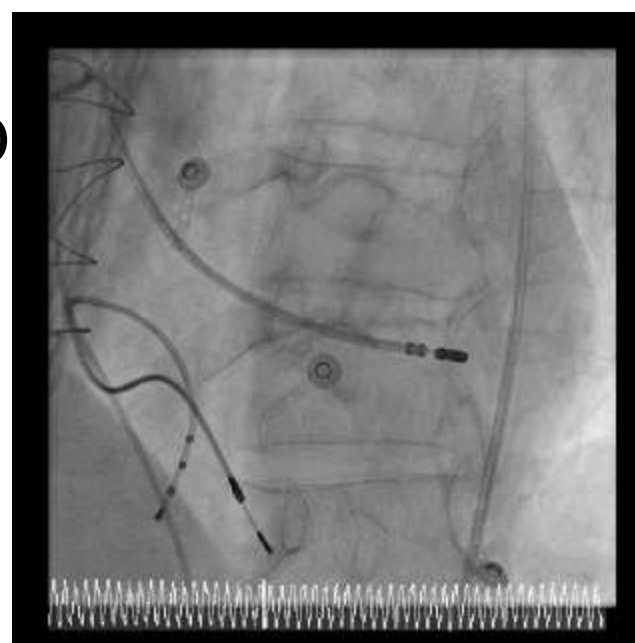
Pacing



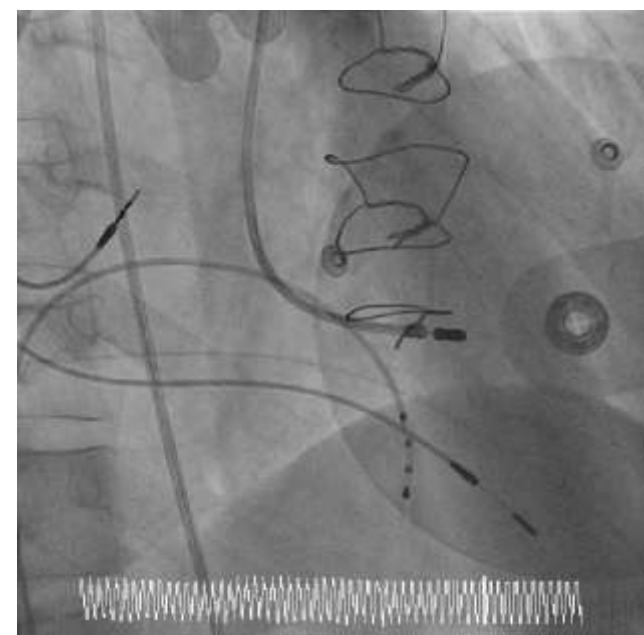

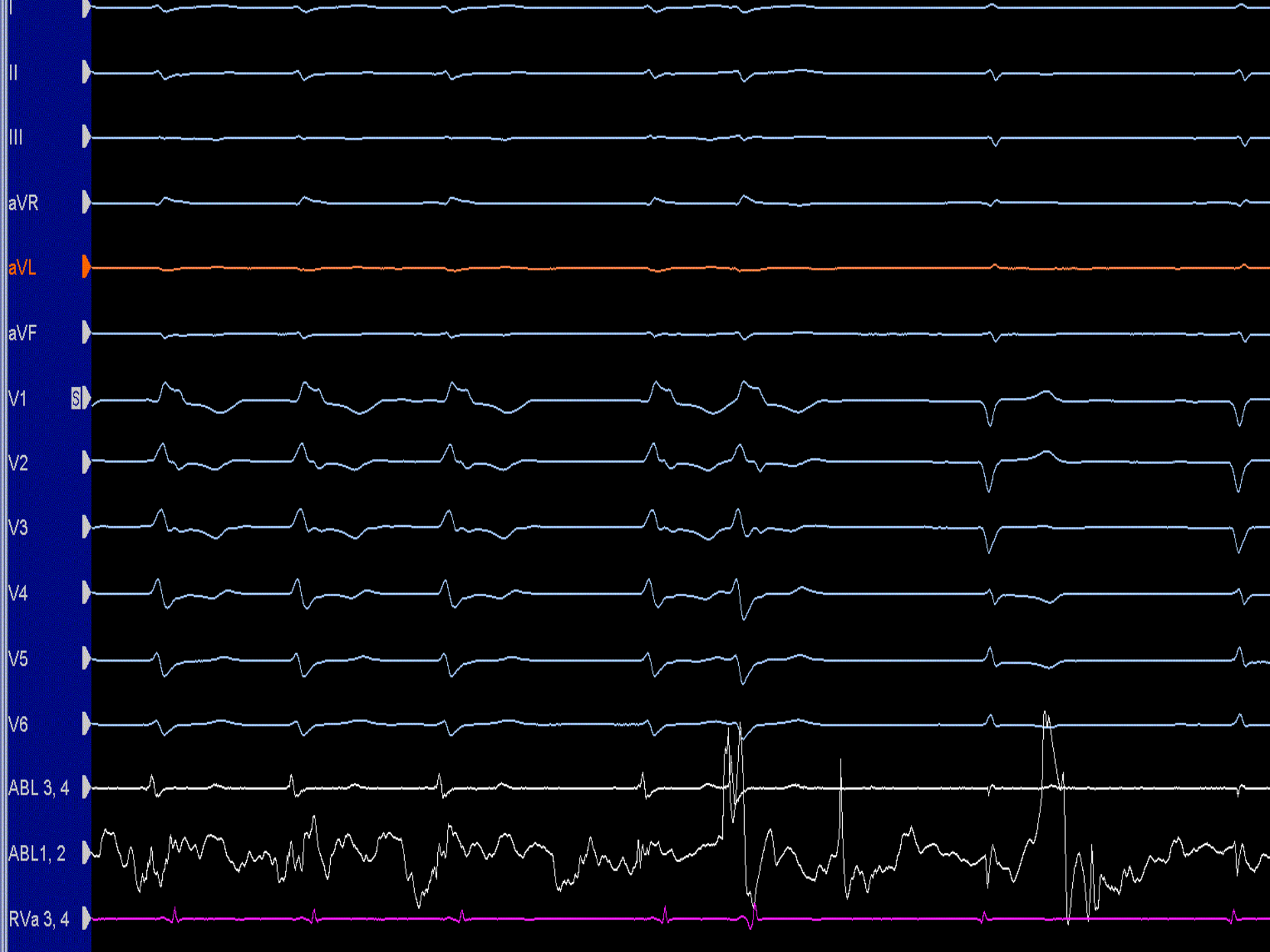


LAO



RAO





Diagnosis

- ▶ Automatic VT from postero-lateral LV
- ▶ Likely origin from papillary muscle remnant

- ▶ Well with no recurrence 3 months post ablation

Ventricular Tachycardia Originating From the Posterior Papillary Muscle in the Left Ventricle: A Distinct Clinical Syndrome

Harish Doppalapudi, Takumi Yamada, H. Thomas McElderry, Vance J. Plumb,

Andrew E. Epstein and G. Neal Kay

Circ Arrhythm Electrophysiol 2008;1;23-29

